Autonomic Nervous System (ANS)

(Note: In addition to VE nerurons, GVA neuons (and even CNS components) may be included under ANS.)

Visceral Efferent (VE) Pathway: involves 2 neurons

1) *preganglionic* neuron — cell body located in CNS; axon synapses in an autonomic ganglia
2) *postganglionic* neuron — cell body in an autonomic ganglion; axon innervates smooth muscle, cardiac muscle or gland

Note: The preganglionic neuron always releases acetylcholine at its synaptic terminals. The postganglionic neuron releases acetylcholine or norepinephrine (noradrenalin) as its transmitter chemical to excite target cells.

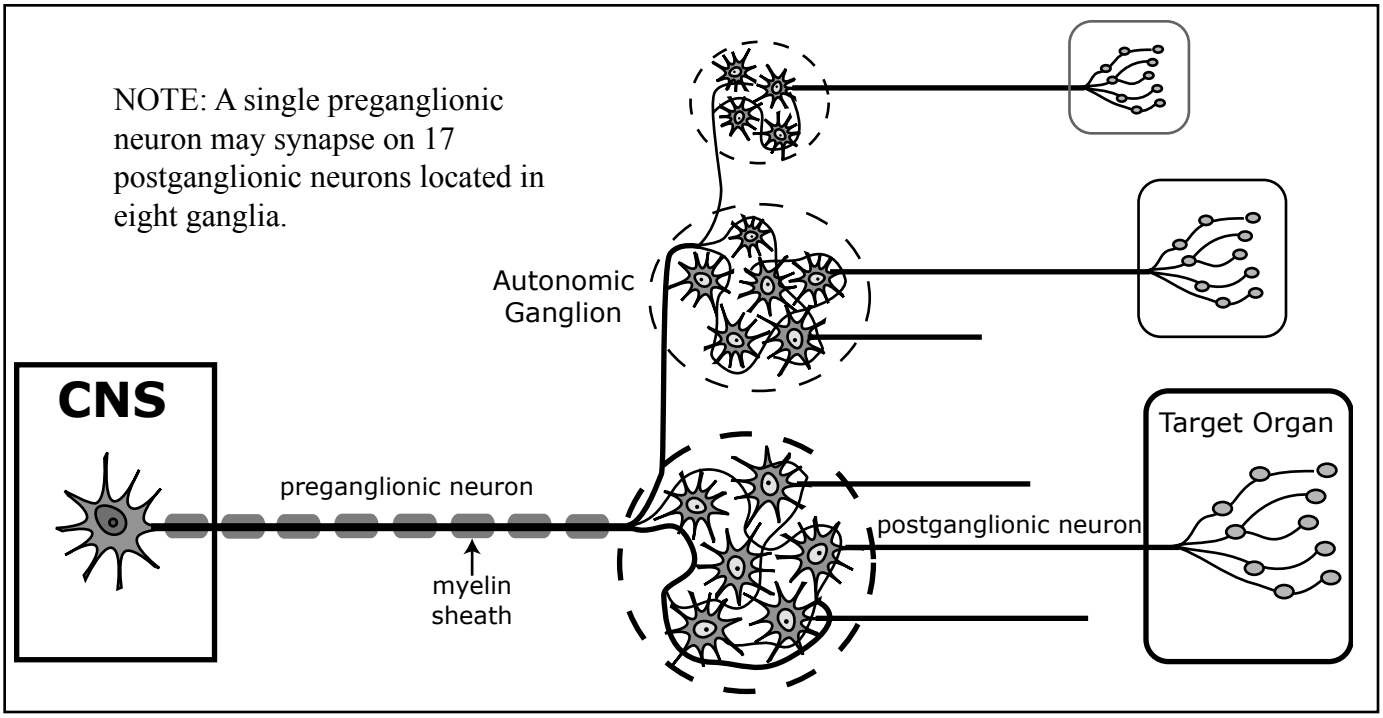

ANS Divisions: basis for recognizing two divisions

Feature	Sympathetic	Parasympathetic
Distribution:	whole body	viscera in body cavities; in head
Preganglionic origin:	thoracolumbar spinal cord	sacral spinal cord & brainstem
Postganglionic neuron:	usually adrenergic	always cholinergic
(Transmitter released:	norepinephrine	acetylcholine)
Functional role:	"fight or flight"	routine visceral operations

Functional Differences:

Structure	Sympathetic	Parasympathetic
iris (pupil)	dilate	constrict
heart	increase rate & force	decrease rate
bronchi	dilate	constrict
gut & bladder wall	inhibit motility	excite contraction
gut & bladder sphincters	contract	relax
cutaneous vessels	constrict	*doesn't innervate*
muscle vessels	dilate (cholinergic)	*doesn't innervate*
sweat glands	secrete	*doesn't innervate*
ALSO:	semen ejaculation	penis erection
	glucose release (liver)	secretion stomach/pancreas

NOTE: A single preganglionic neuron may synapse on 17 postganglionic neurons located in eight ganglia.

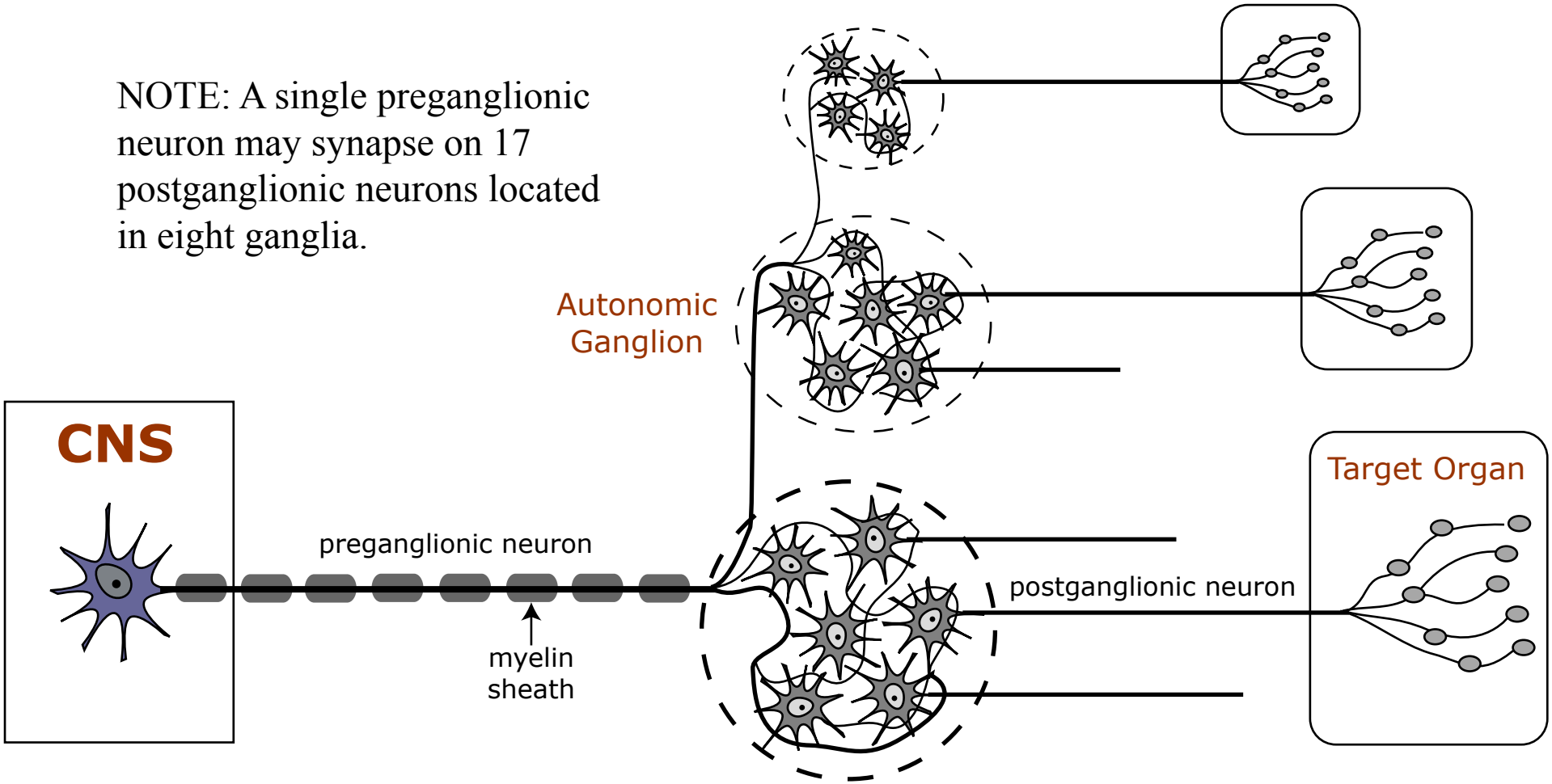

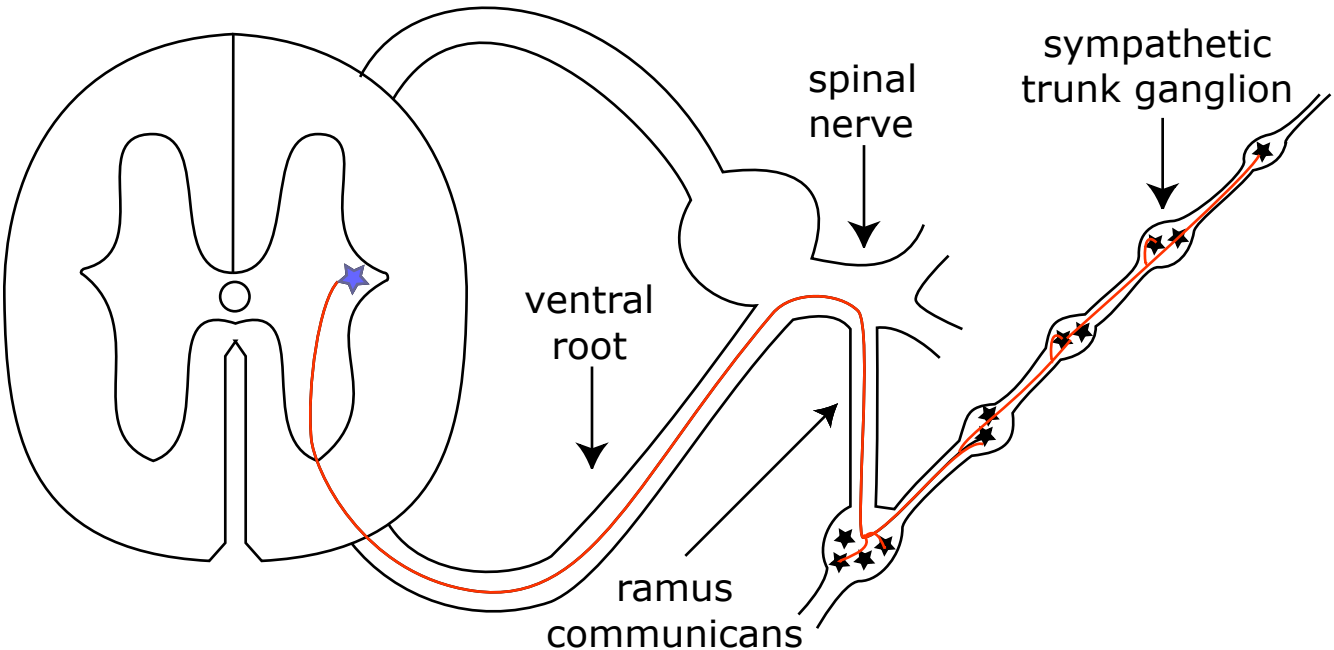
spinal
nerve
sympathetic
trunk ganglion
ventral
root
ramus
communicans

Autonomic Preganglionic Pathways

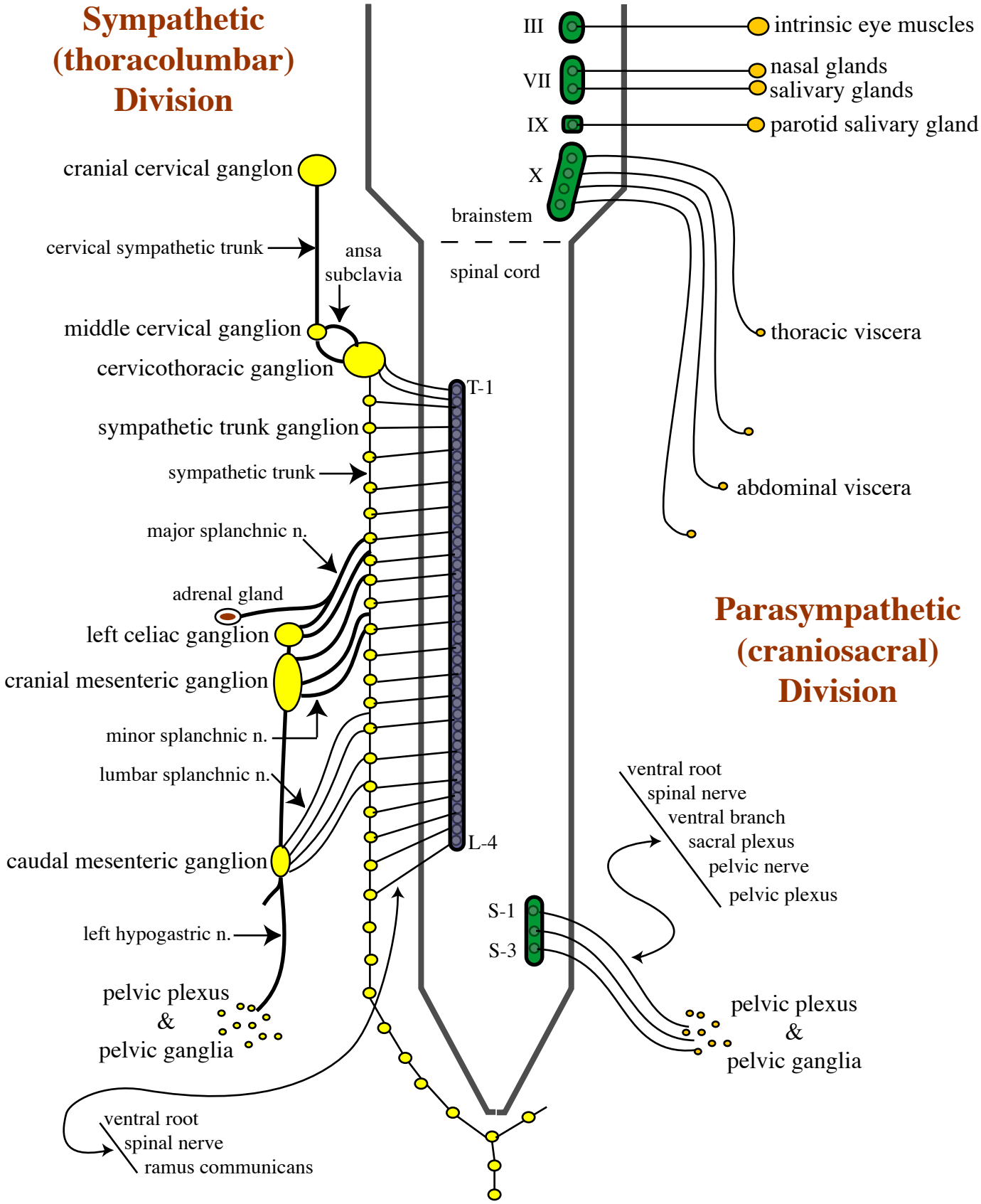

Autonomic Nervous System (ANS)

(Note: In addition to VE nerurons, GVA neuons (and even CNS components) may be included under ANS.)

Visceral Efferent (VE) Pathway: involves 2 neurons

1) *preganglionic* neuron — cell body located in CNS; axon synapses in an autonomic ganglia
2) *postganglionic* neuron — cell body in an autonomic ganglion; axon innervates smooth muscle, cardiac muscle or gland

Note: The preganglionic neuron always releases acetylcholine at its synaptic terminals. The postganglionic neuron releases acetylcholine or norepinephrine (noradrenalin) as its transmitter chemical to excite target cells.

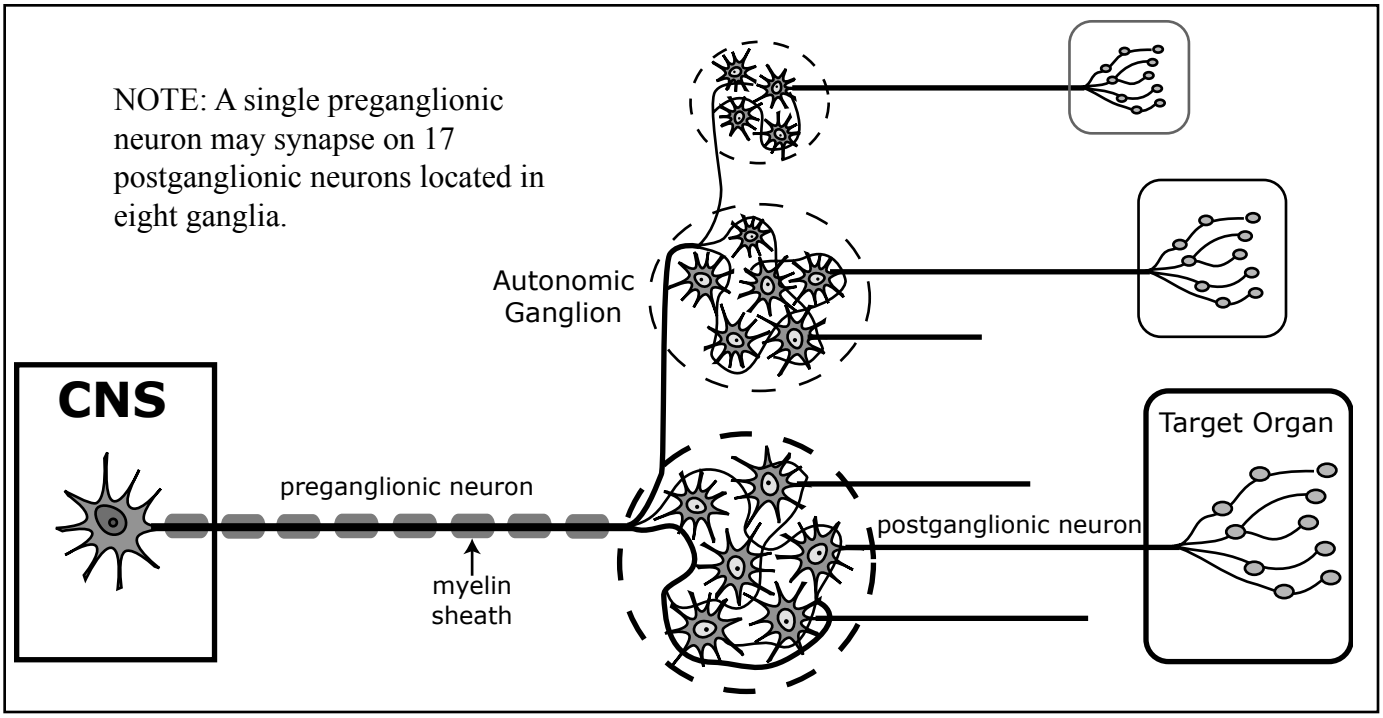

ANS Divisions: basis for recognizing two divisions

Feature	Sympathetic	Parasympathetic
Distribution:	whole body	viscera in body cavities; in head
Preganglionic origin:	thoracolumbar spinal cord	sacral spinal cord & brainstem
Postganglionic neuron:	usually adrenergic	always cholinergic
(Transmitter released:	norepinephrine	acetylcholine)
Functional role:	"fight or flight"	routine visceral operations

Functional Differences:

Structure	Sympathetic	Parasympathetic
iris (pupil)	dilate	constrict
heart	increase rate & force	decrease rate
bronchi	dilate	constrict
gut & bladder wall	inhibit motility	excite contraction
gut & bladder sphincters	contract	relax
cutaneous vessels	constrict	*doesn't innervate*
muscle vessels	dilate (cholinergic)	*doesn't innervate*
sweat glands	secrete	*doesn't innervate*
ALSO:	semen ejaculation	penis erection
	glucose release (liver)	secretion stomach/pancreas

Autonomic Preganglionic Pathways

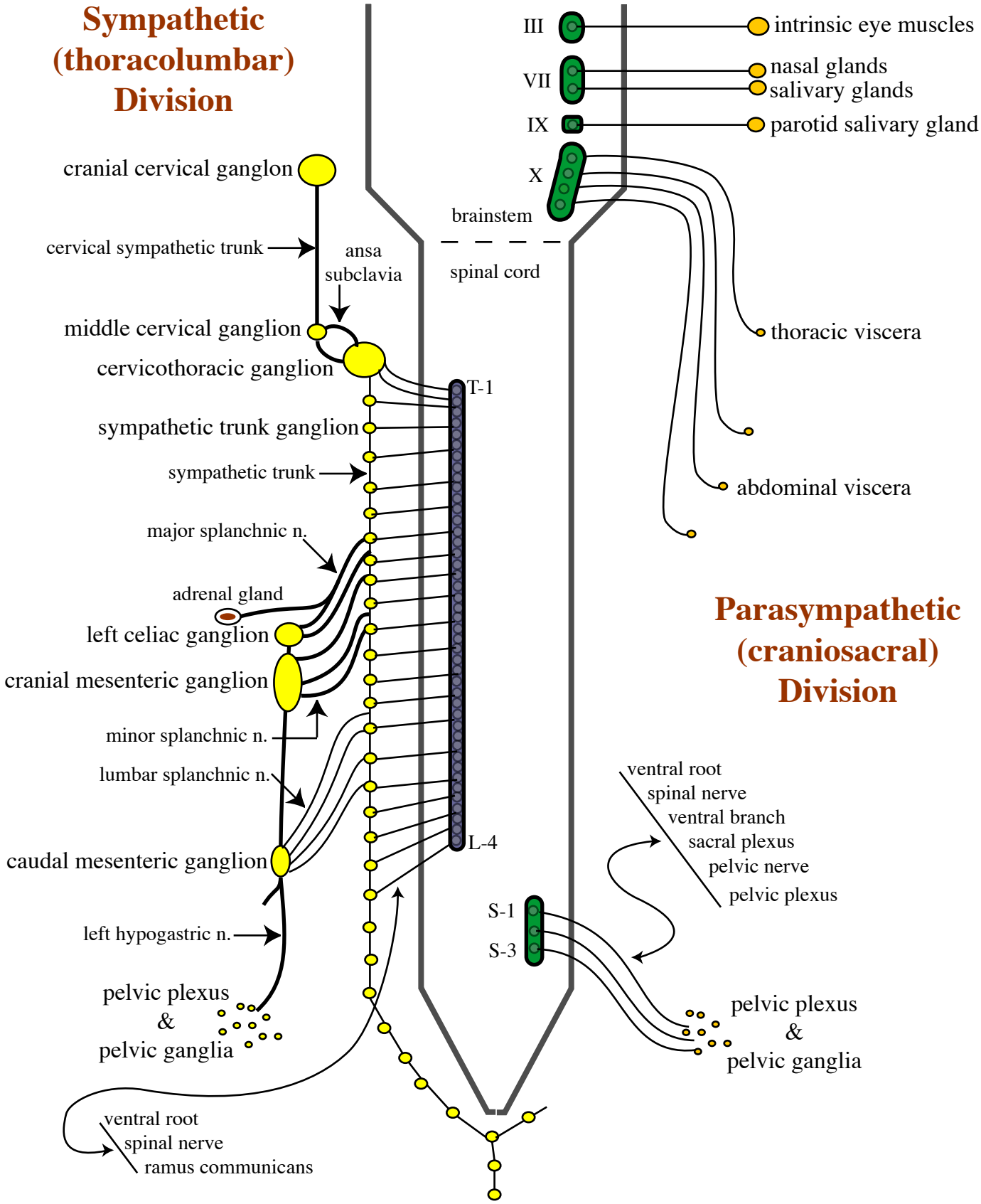

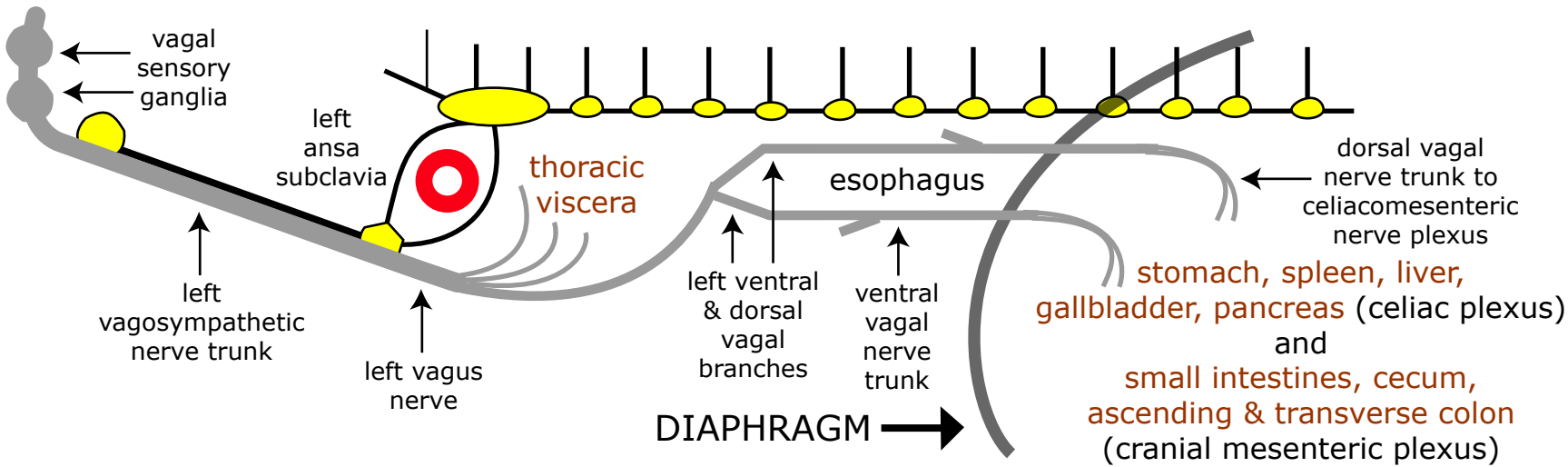

NOTE: Postganglionic neurons are in terminal ganglia located within submucosal & myenteirc nerve plexuses

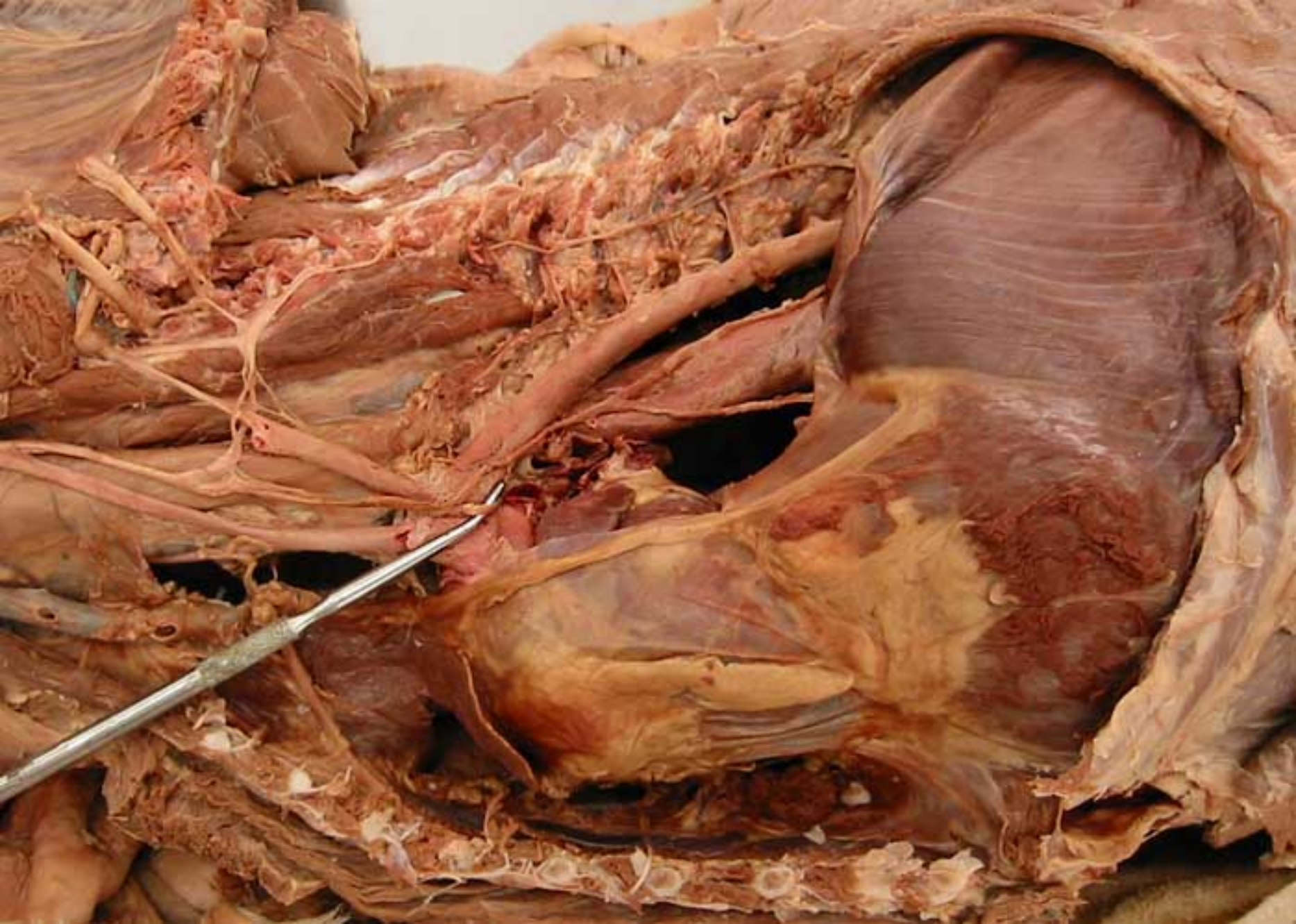

The **sympathetic** division is activated when the brain perceives a situation that is "life threatening", i.e., a situation that calls for mobilization of physiological resources in preparation for a great expenditure of energy to escape or combat the threat.
The **parasympathetic** role is to restore & maintain routine visceral operations.

Autonomic Pathways

NOTE: Visceral afferent axons use same pathways as visceral efferents

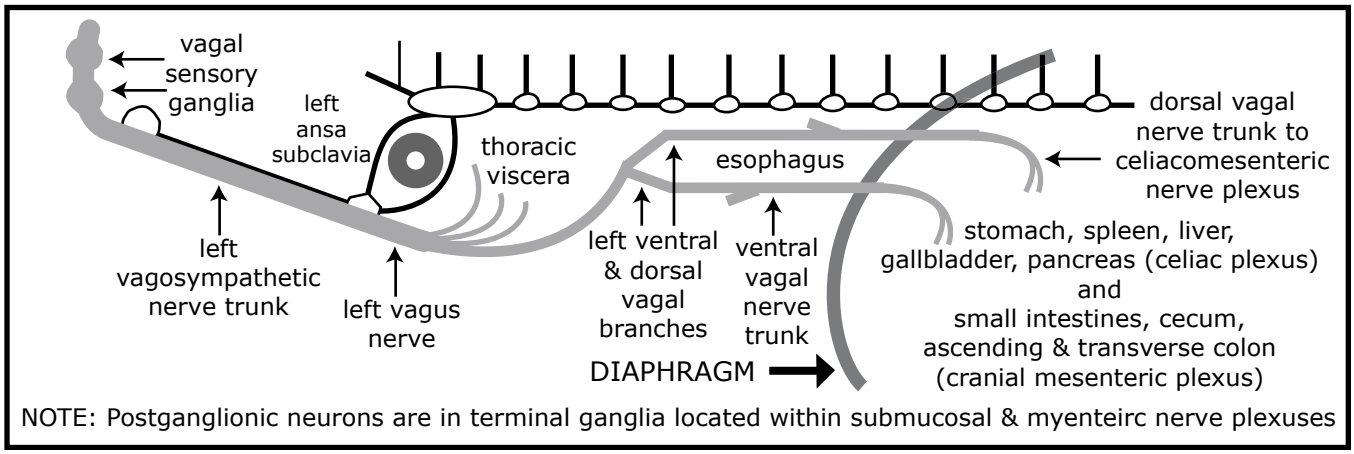

Parasympathetic pathways:

1] **Cranial nerves III, VII, and IX** .... *later in the course*.

2] **Cranial nerve X** (vagus nerve) innervates thoracic and abdominal viscera:
Preganglionic pathway: the vagus n. branches travel to organs being innervated
Synapse: occurs within organs innervated, in microscopic terminal ganglia
Postganglionic pathway: axons course in submucosal or myenteric plexuses to reach innervation targets (smooth m., cardiac m. or gland cells).

3] **Sacral spinal cord** innervates pelvic viscera:
Preganglionic pathway: from the sacral cord to pelvic plexus (via ventral root; spinal nerve; ventral branch; sacral plexus; pelvic nerve).
Synapse: occurs in a pelvic ganglion within the pelvic plexus (or in the organ innervated)
Postganglionic pathway: branches from the pelvic plexus run directly to pelvic viscera.

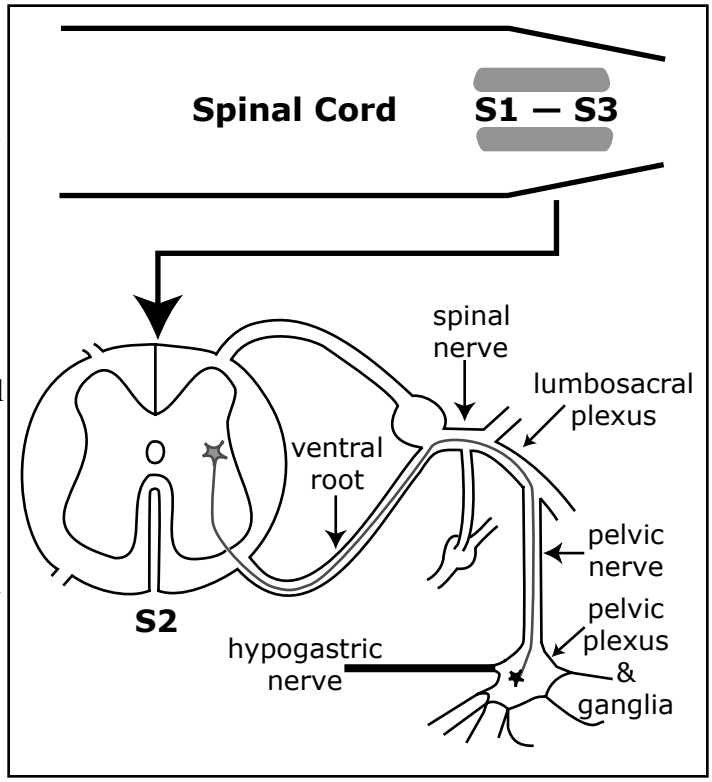

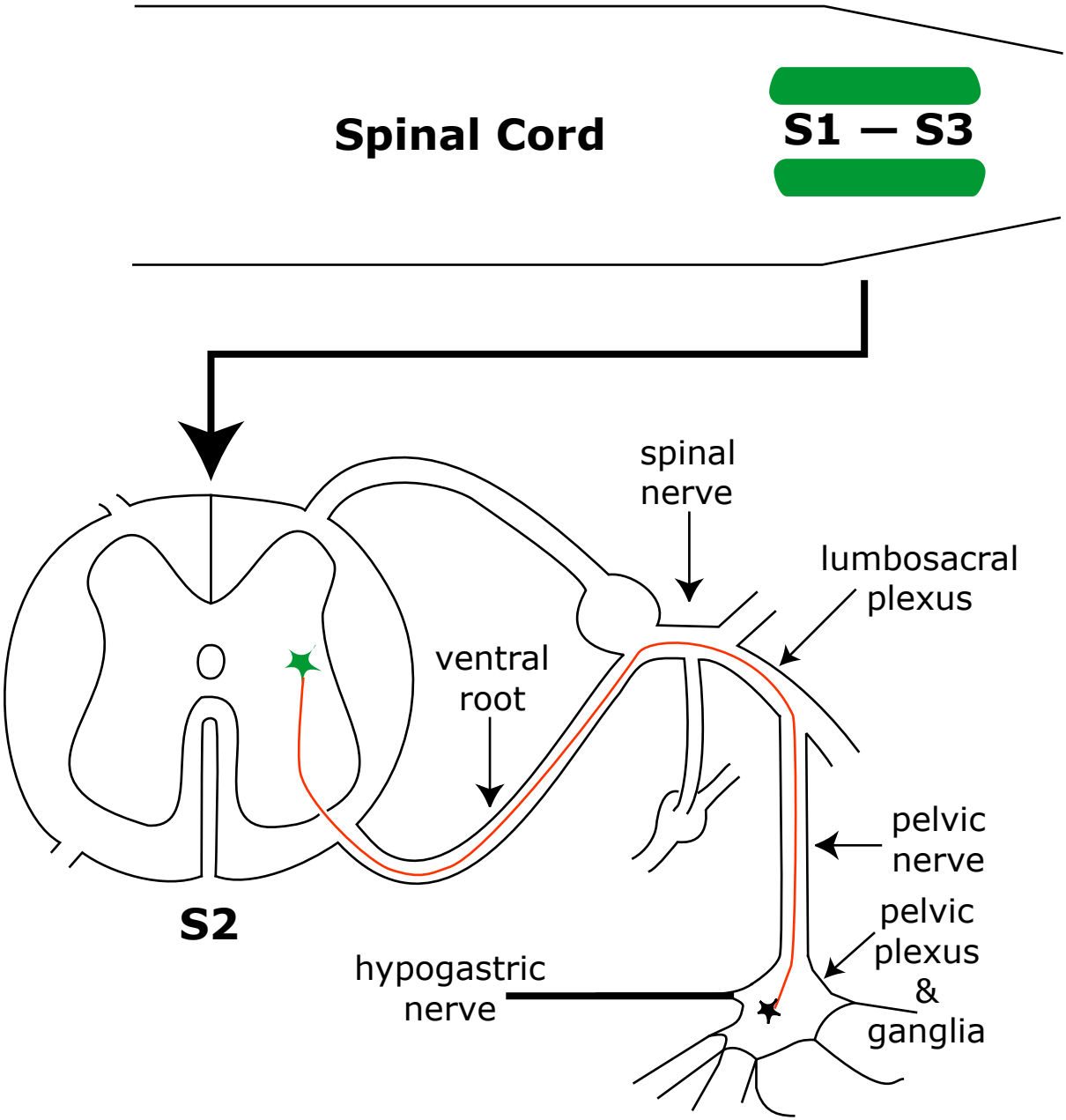
Spinal Cord
S1 — S3
spinal nerve
lumbosacral plexus
ventral root
pelvic nerve
pelvic plexus & ganglia
S2
hypogastric nerve

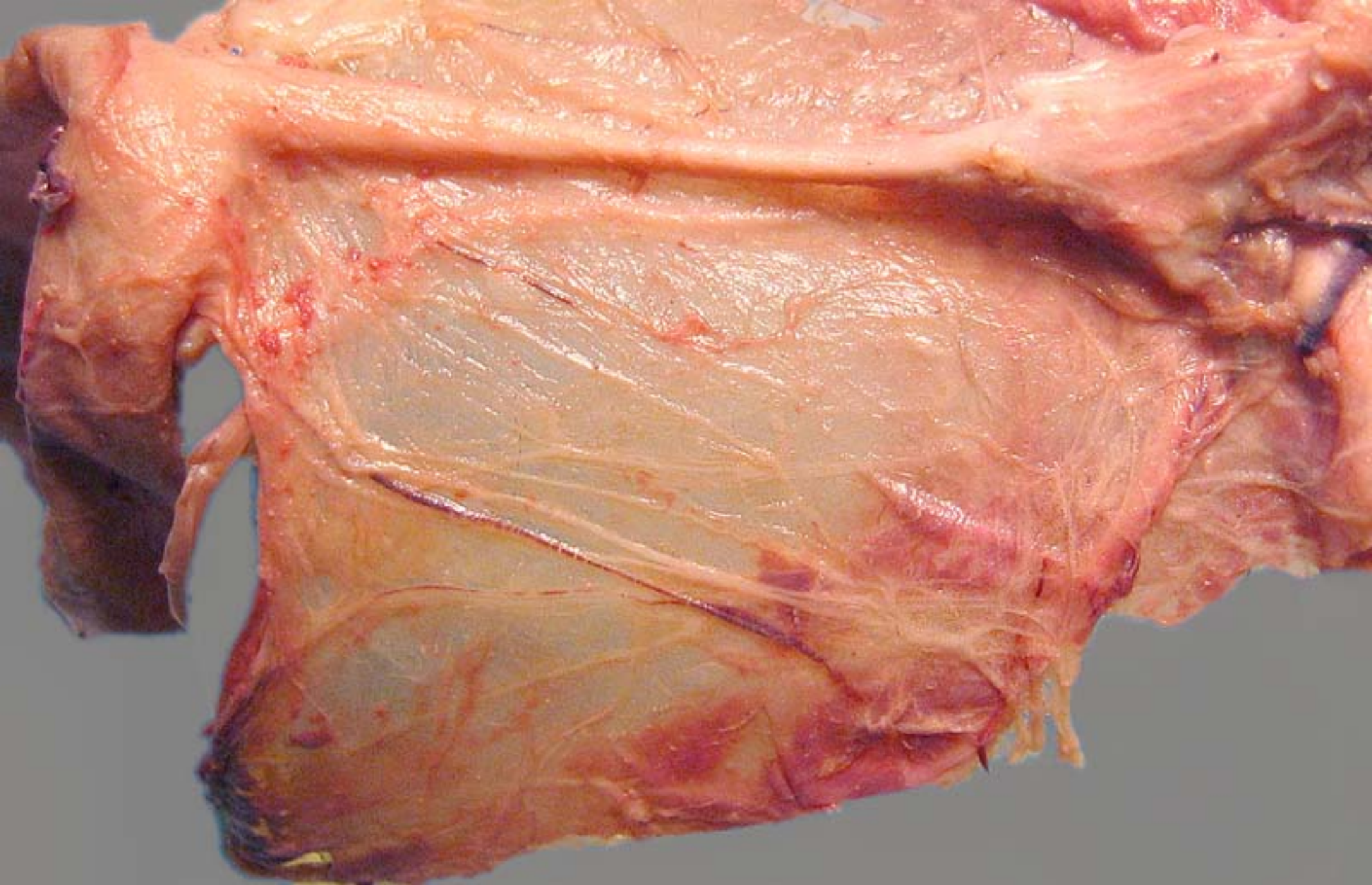

Sympathetic Preganglionic Pathways

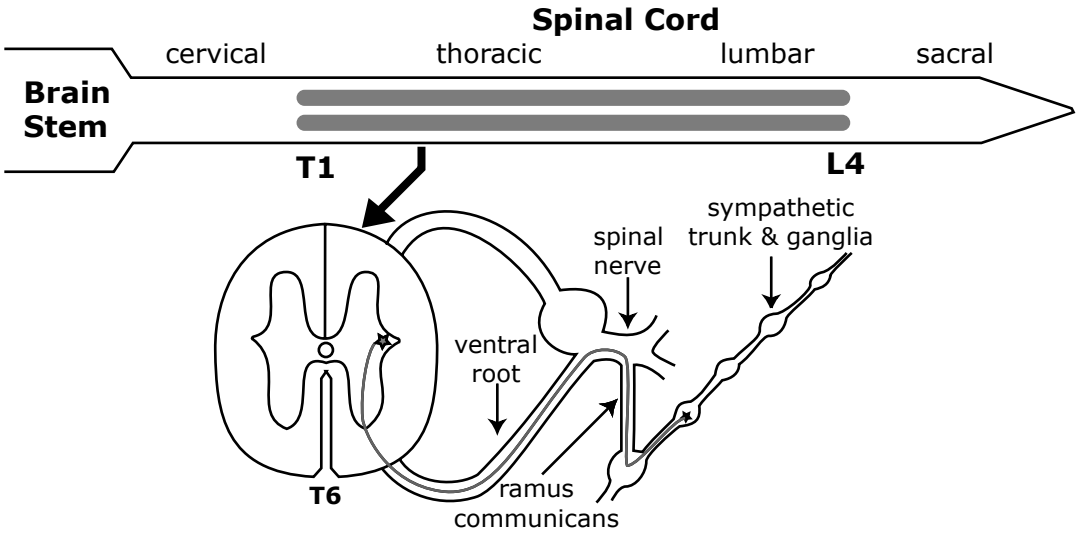

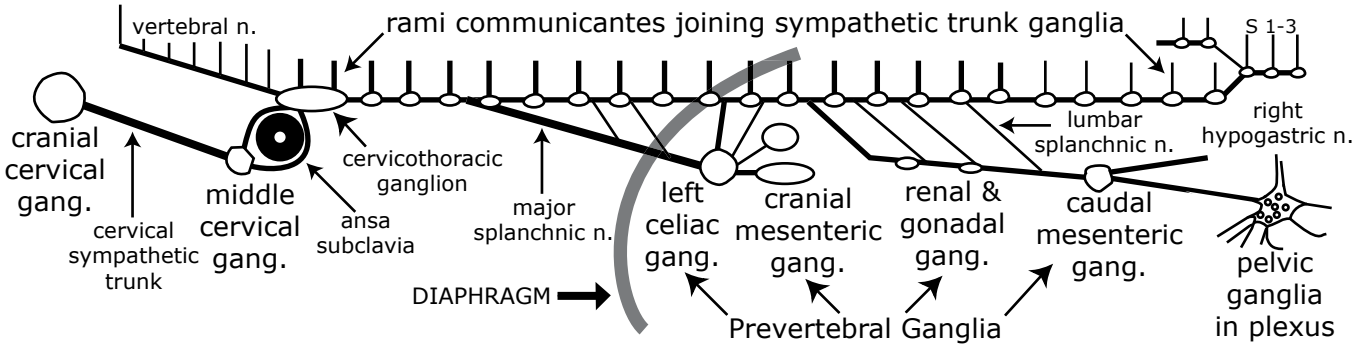

Sympathetic Pathways to Six Regions

Head Region

Presynaptic path:

ventral root; spinal n.; ramus communicans; sympathetic trunk; ansa subclavia; and cervical sympathetic trunk

Synapse:

cranial cervical ganglion

Postsynaptic path:

nerve plexuses run on external & internal carotid arteries and their branches to reach target structures

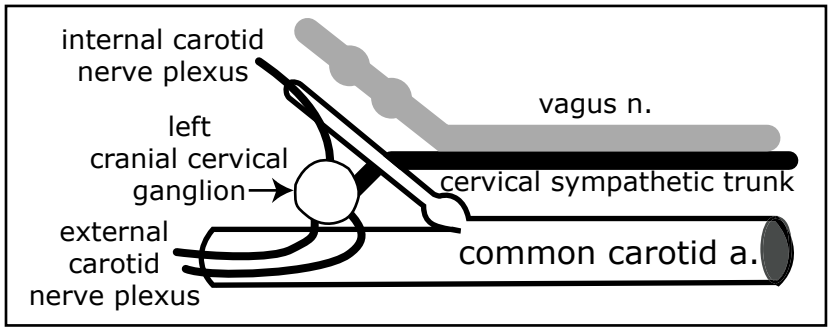

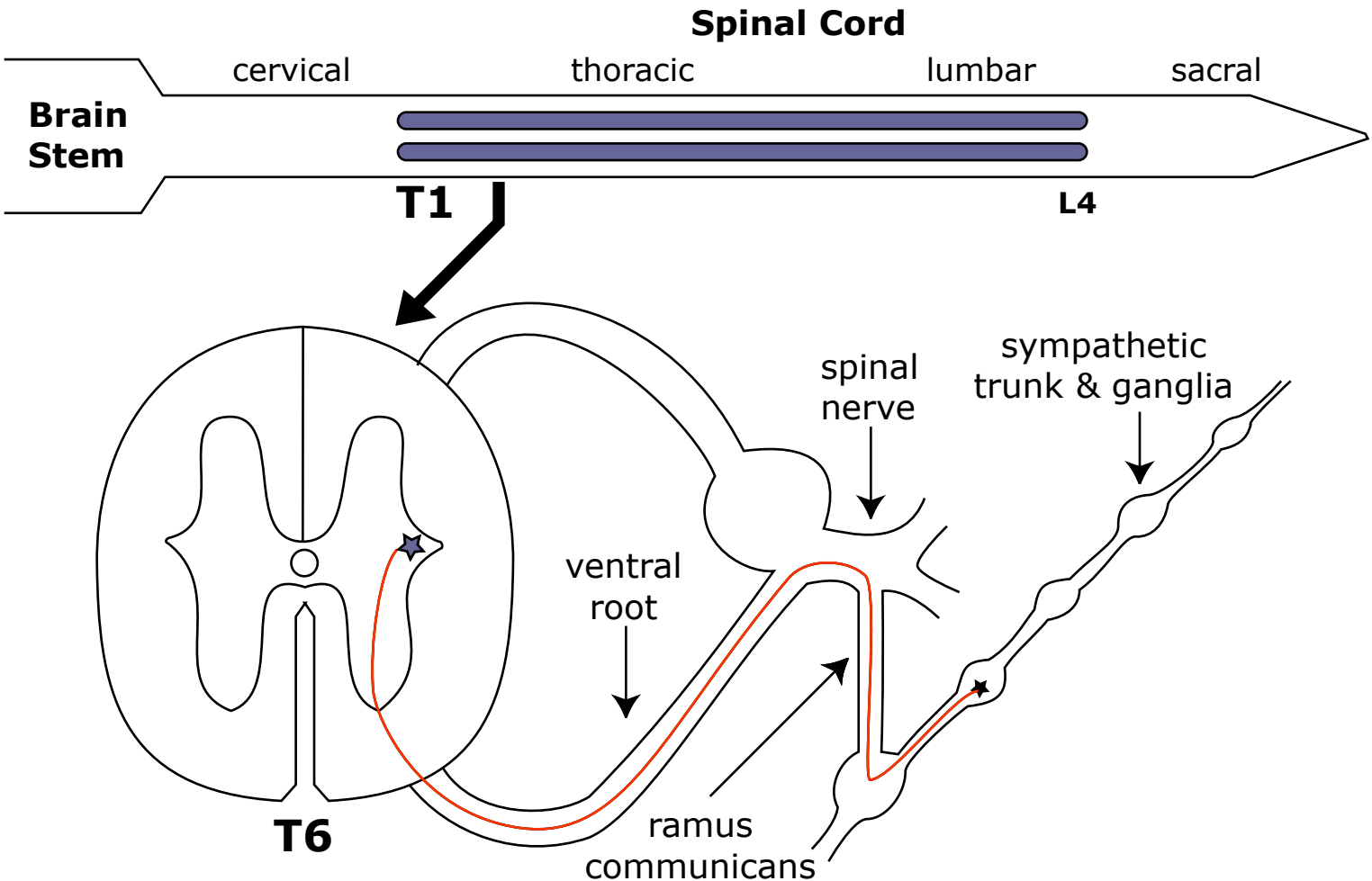
Spinal Cord
cervical
thoracic
lumbar
sacral
Brain Stem
T1
L4
spinal nerve
sympathetic trunk & ganglia
ventral root
ramus communicans
T6

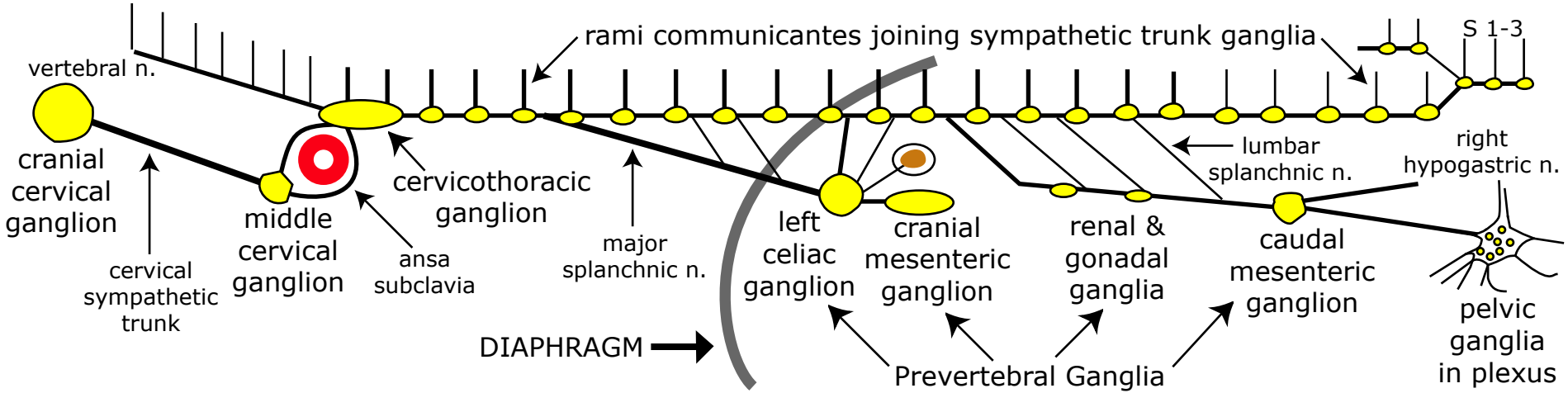
rami communicantes joining sympathetic trunk ganglia
S 1-3
vertebral n.
cranial cervical ganglion
cervical sympathetic trunk
middle cervical ganglion
ansa subclavia
cervicothoracic ganglion
major splanchnic n.
DIAPHRAGM
left celiac ganglion
cranial mesenteric ganglion
renal & gonadal ganglia
Prevertebral Ganglia
lumbar splanchnic n.
caudal mesenteric ganglion
right hypogastric n.
pelvic ganglia in plexus

Sympathetic Preganglionic Pathways

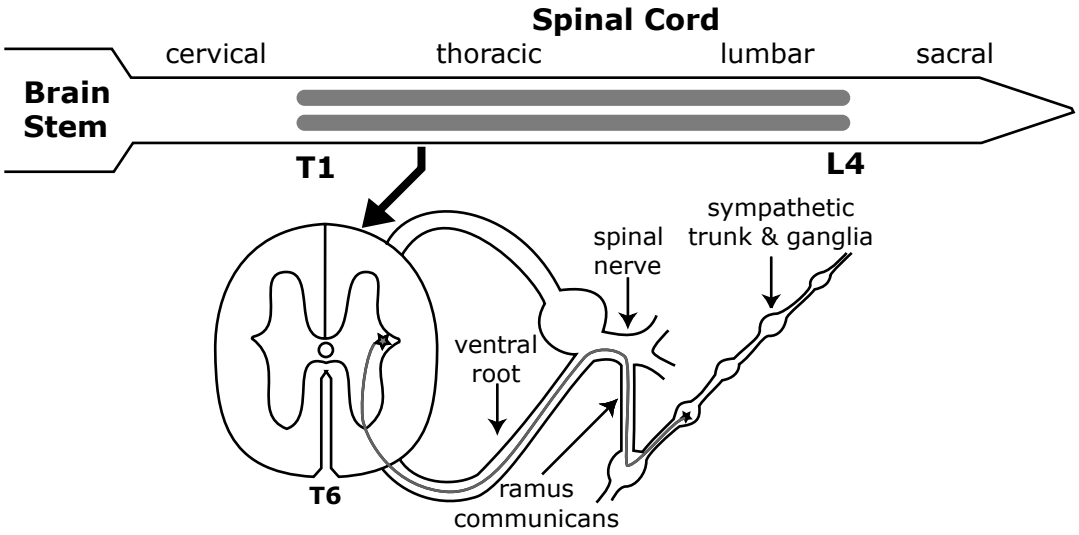

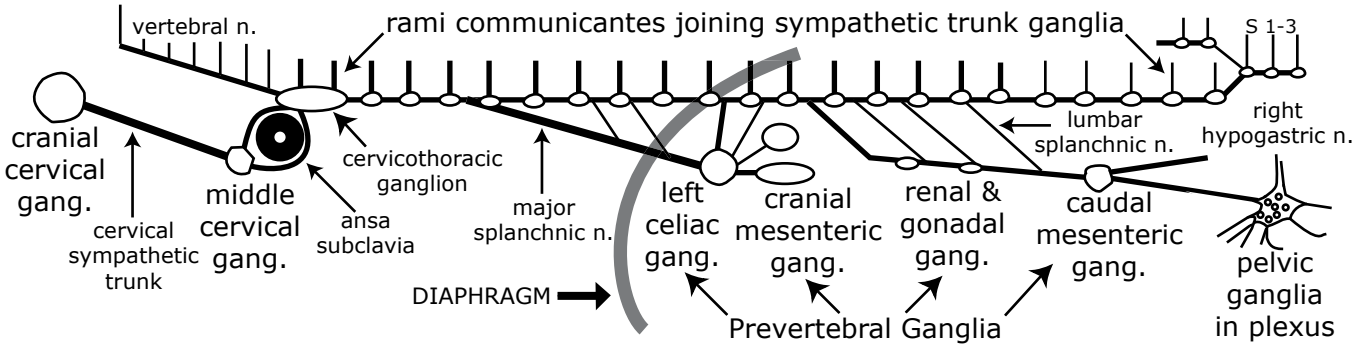

Sympathetic Pathways to Six Regions

Head Region

Presynaptic path:

ventral root; spinal n.; ramus communicans; sympathetic trunk; ansa subclavia; and cervical sympathetic trunk

Synapse:

cranial cervical ganglion

Postsynaptic path:

nerve plexuses run on external & internal carotid arteries and their branches to reach target structures

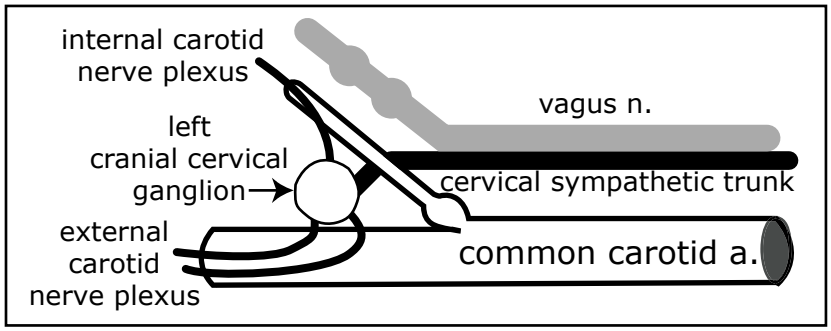

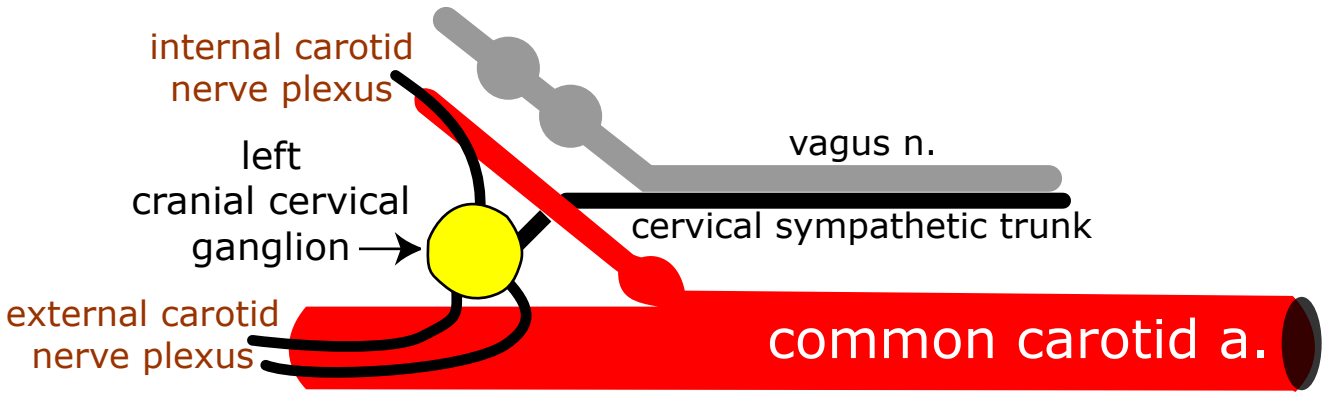
internal carotid
nerve plexus
left
cranial cervical
ganglion
external carotid
nerve plexus
vagus n.
cervical sympathetic trunk
common carotid a.

Neck Region

Presynaptic path:
ventral root; spinal n.; ramus communicans; sympathetic trunk
Synapse:
cervicothoracic ganglion
Postsynaptic path:
vertebral nerve; rami communicantes; cervical spinal nn.; dorsal or ventral branches to muscles & skin

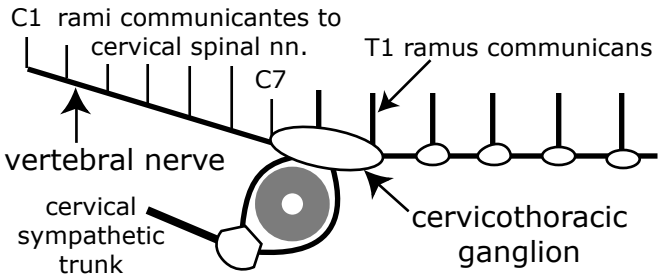

Body Wall and Limbs and Tail

Presynaptic path:
ventral root; spinal n.; ramus communicans; sympathetic trunk

Synapse:
sympathetic trunk ganglia (paravertebral ganglia)

Postsynaptic path:
rami communicantes; spinal nn.; dorsal or ventral branches to muscles & skin

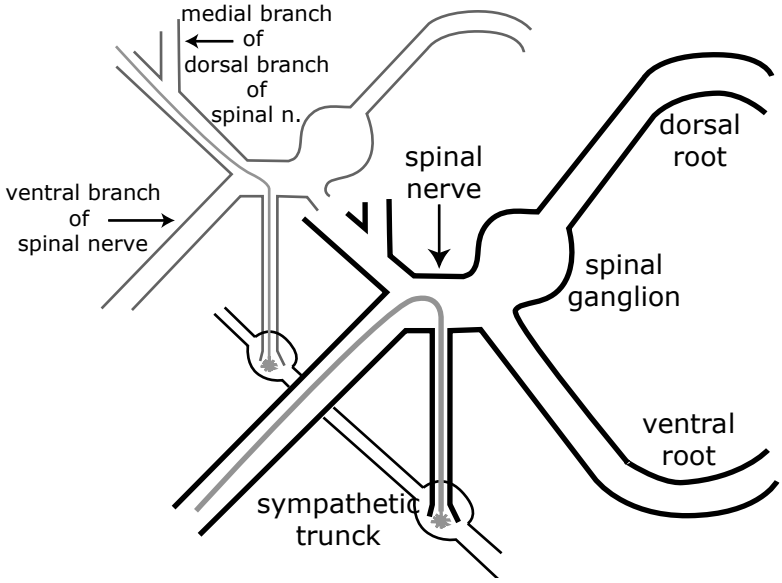

Thoracic Viscera

Presynaptic path: ventral root; spinal n.; ramus communicans; sympathetic trunk
Synapse: cervicothoracic & middle cervical ganglia
Postsynaptic path: cardiosympathetic nn. branch from ansa subclavia (also, branches that run with vagus n.)

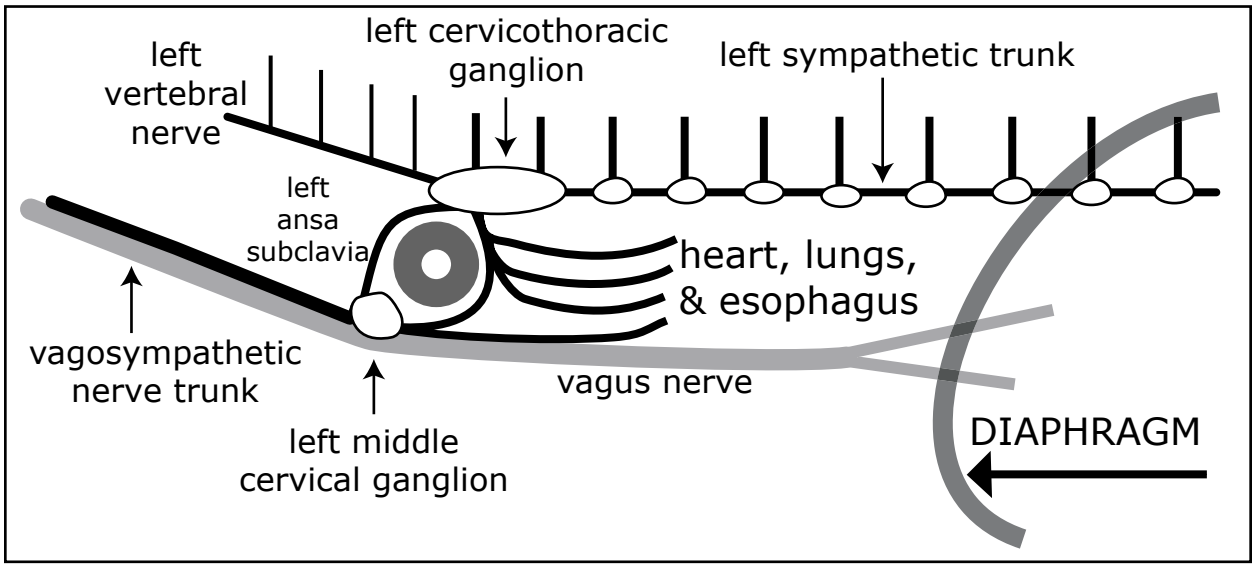

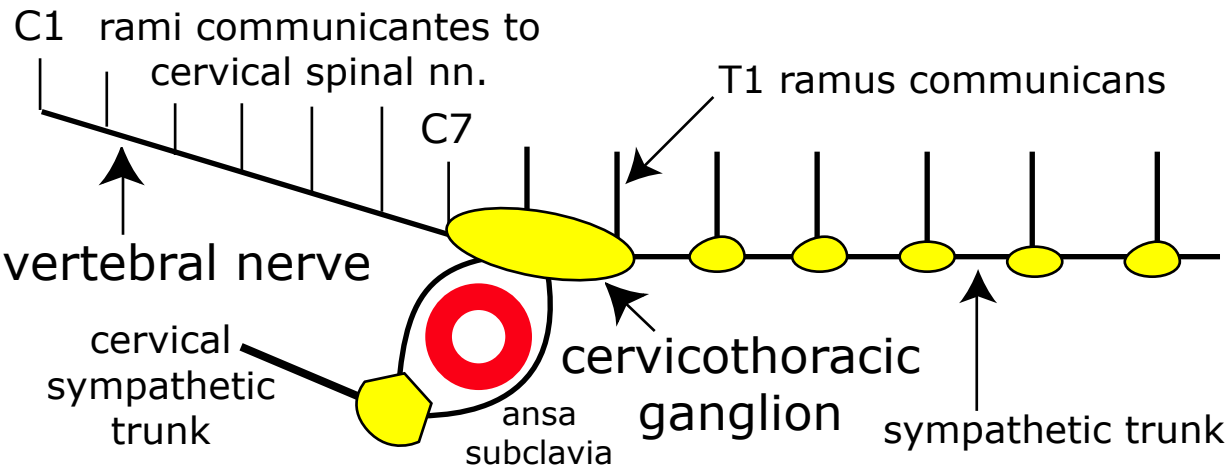
C1
rami communicantes to
cervical spinal nn.
C7
T1 ramus communicans
vertebral nerve
cervical
sympathetic
trunk
ansa
subclavia
cervicothoracic
ganglion
sympathetic trunk

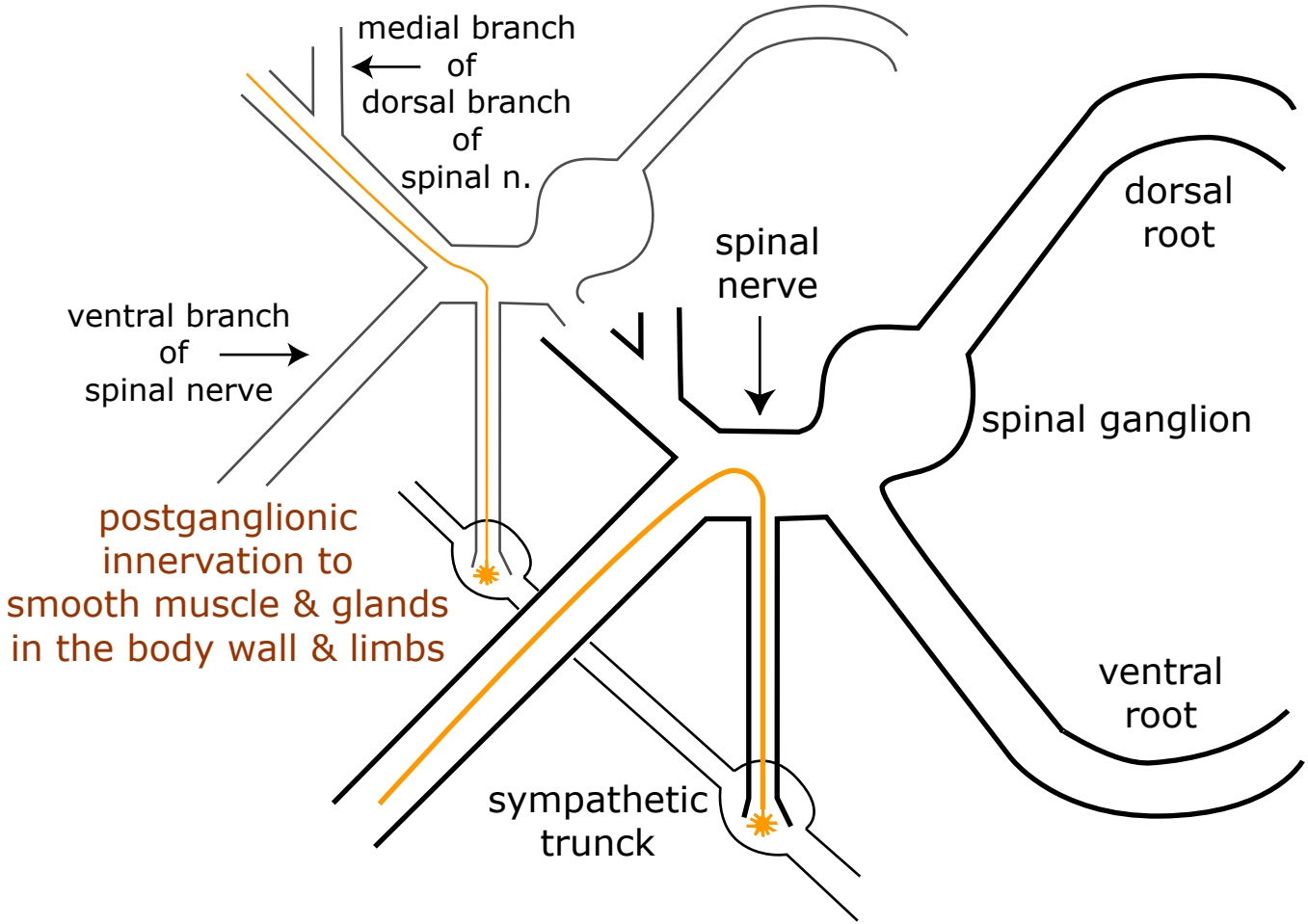
medial branch
of
dorsal branch
of
spinal n.
ventral branch
of
spinal nerve
spinal
nerve
dorsal
root
spinal ganglion
postganglionic
innervation to
smooth muscle & glands
in the body wall & limbs
ventral
root
sympathetic
trunck

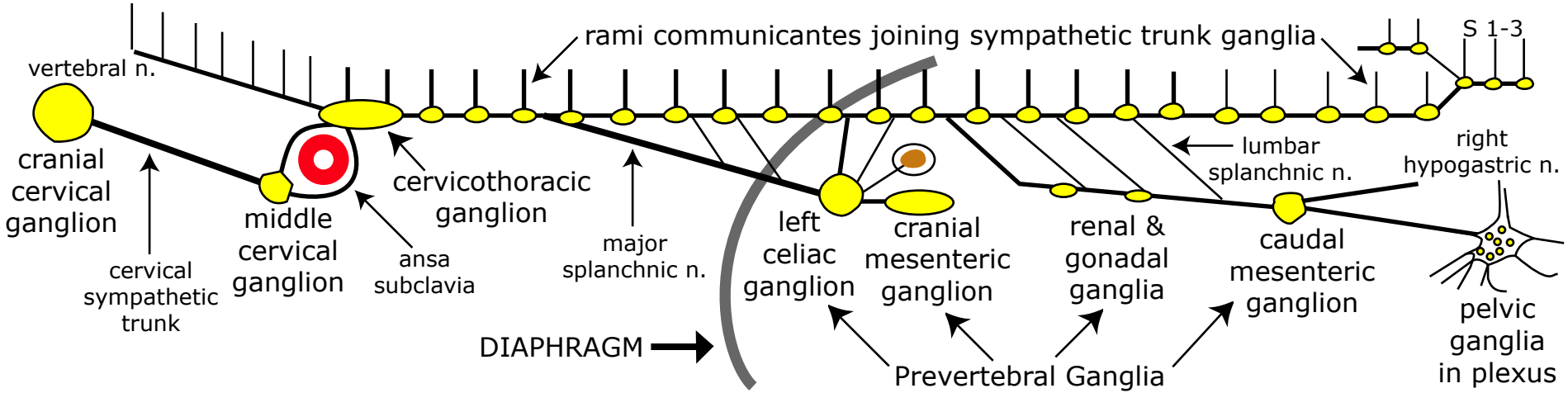
rami communicantes joining sympathetic trunk ganglia
S 1-3
vertebral n.
cranial cervical ganglion
cervical sympathetic trunk
middle cervical ganglion
ansa subclavia
cervicothoracic ganglion
major splanchnic n.
DIAPHRAGM
left celiac ganglion
cranial mesenteric ganglion
renal & gonadal ganglia
Prevertebral Ganglia
lumbar splanchnic n.
caudal mesenteric ganglion
right hypogastric n.
pelvic ganglia in plexus

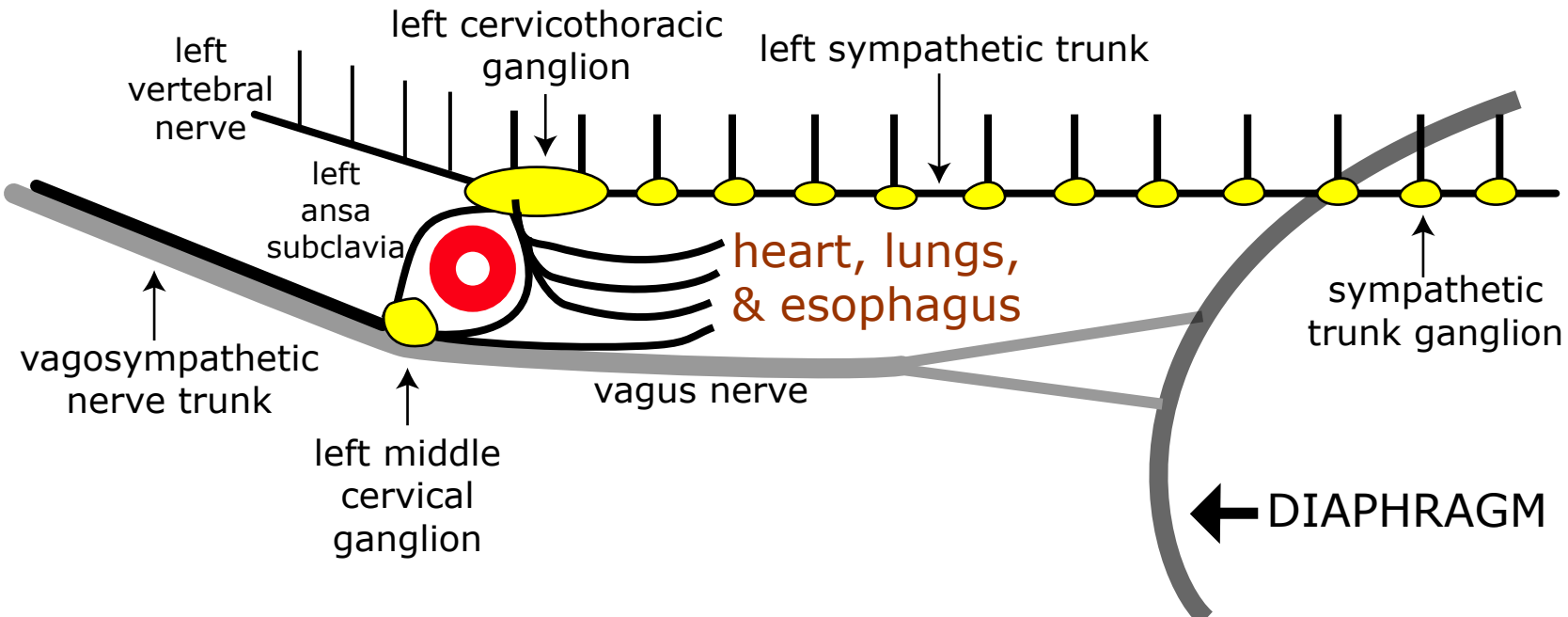
left cervicothoracic ganglion
left sympathetic trunk
left vertebral nerve
left ansa subclavia
heart, lungs, & esophagus
sympathetic trunk ganglion
vagosympathetic nerve trunk
vagus nerve
left middle cervical ganglion
DIAPHRAGM

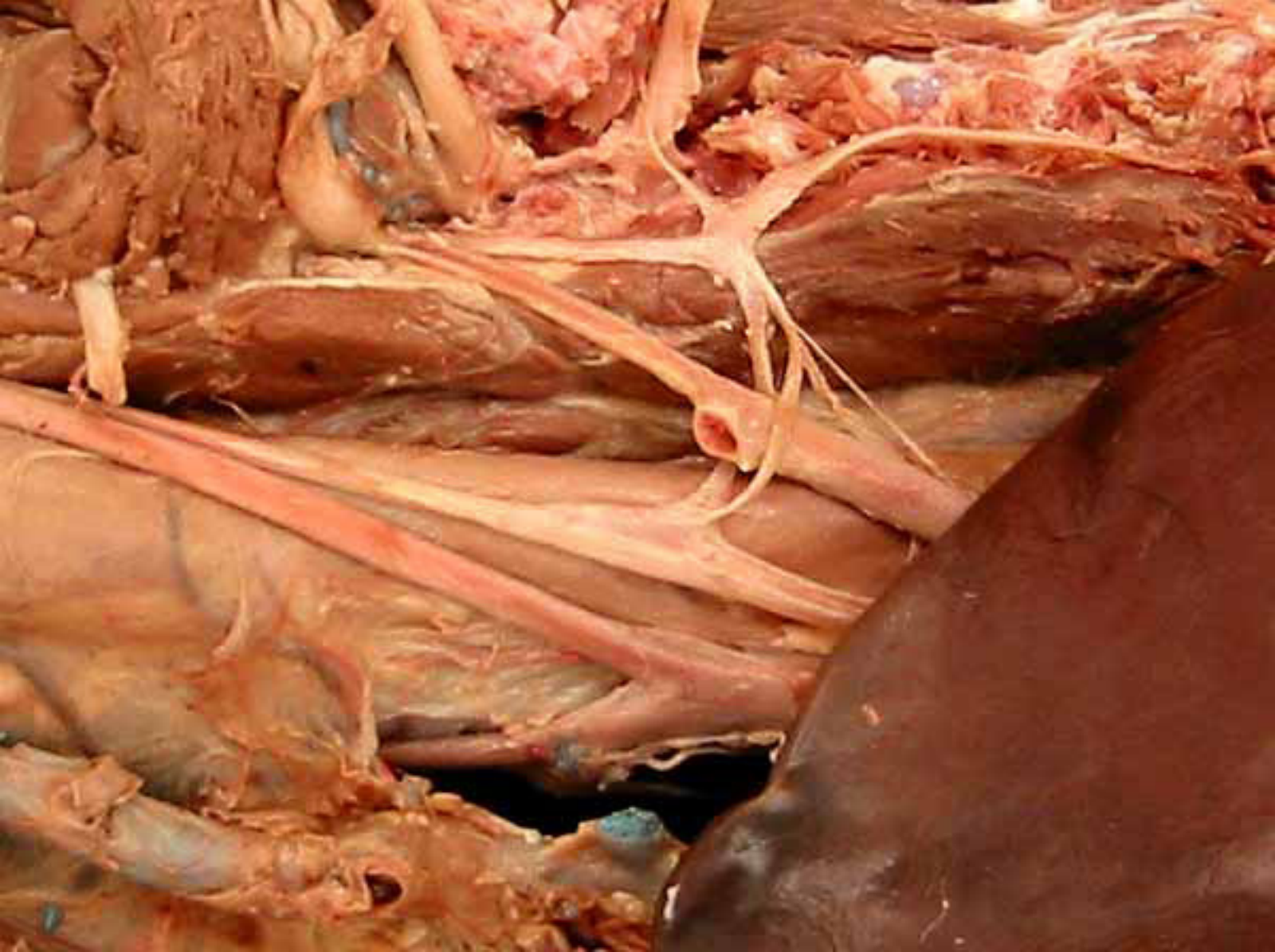

Abdominal Viscera

Presynaptic path: ventral root; spinal n.; ramus communicans; sympathetic trunk; splanchnic nn.

Synapse: prevertebral ganglia (left/right celiac, cranial mesenteric, caudal mesenteric, renal, and gonadal ganglia) located in nerve plexuses along the aorta

Postsynaptic path: nerve plexuses on abdominal arteries supplying particular organs

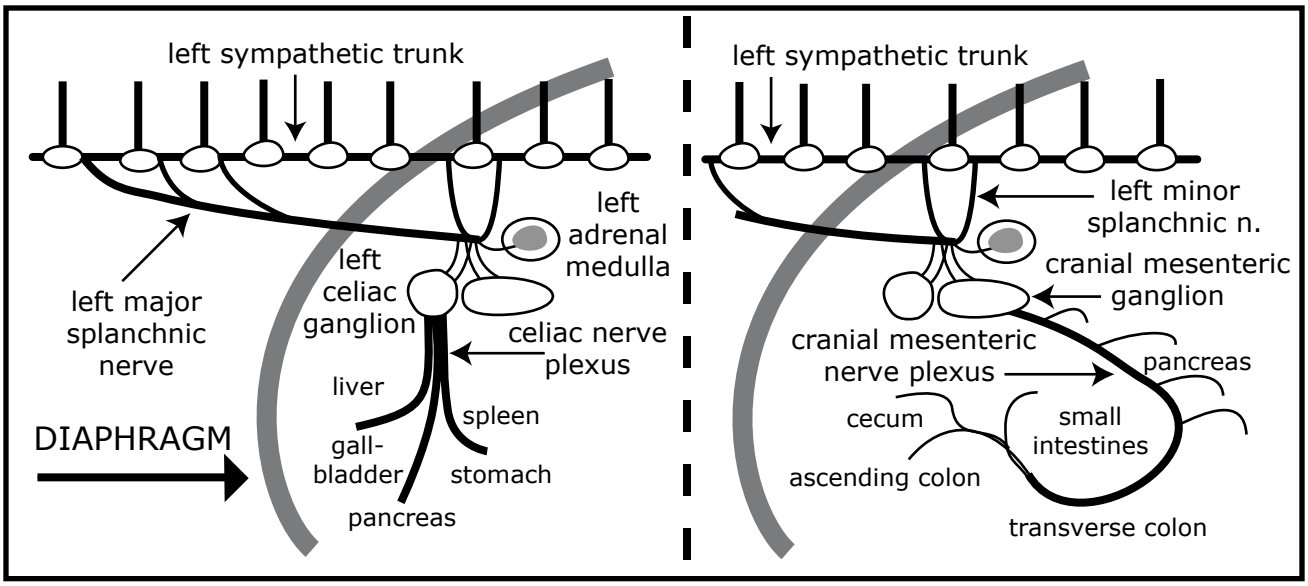

Pelvic Viscera

Presynaptic path: ventral root; spinal n.; ramus communicans; sympathetic trunk; lumbar splanchnic nn.; caudal mesenteric plexus

Synapse: caudal mesenteric ganglion (also, synapses in pelvic ganglia)

Postsynaptic path: hypogastric n.; pelvic plexus; branches directly to pelvic viscera (left/right)

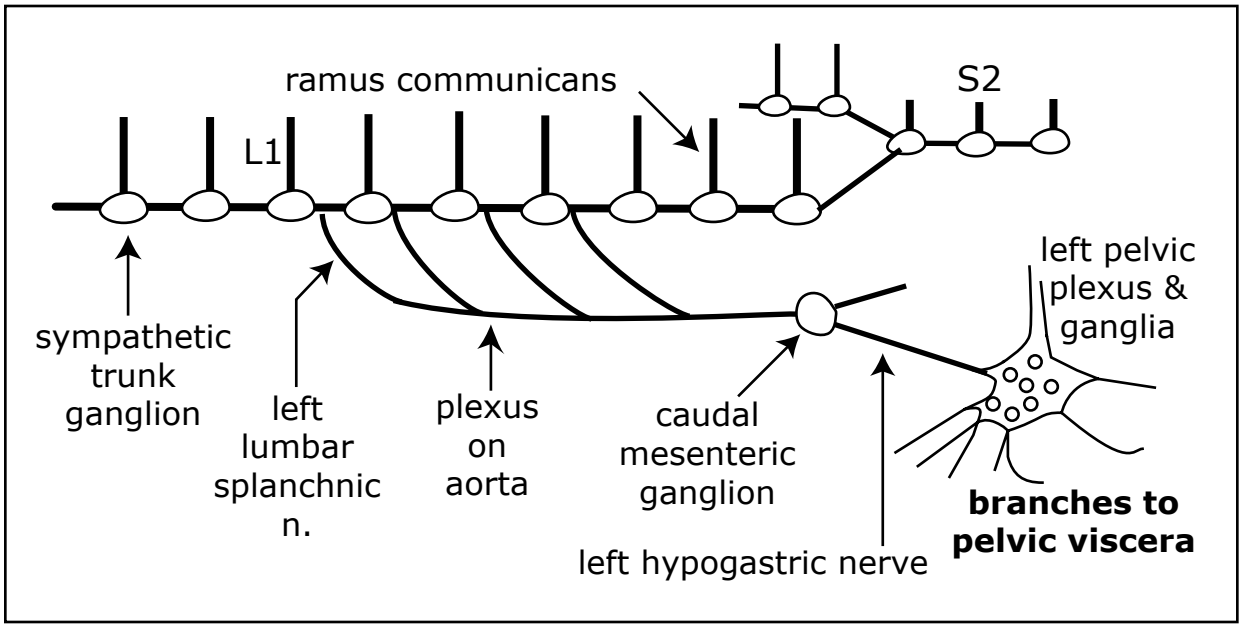

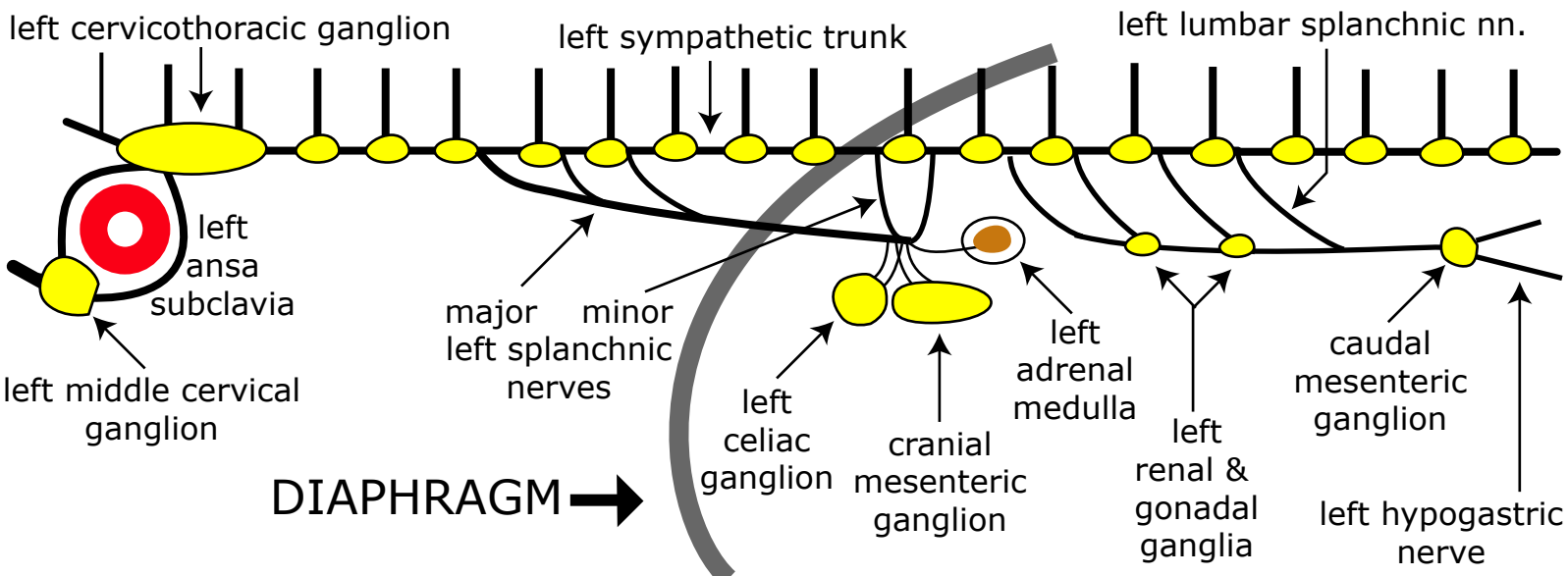
left cervicothoracic ganglion
left sympathetic trunk
left lumbar splanchnic nn.
left ansa subclavia
left middle cervical ganglion
major left splanchnic nerves
minor
left celiac ganglion
cranial mesenteric ganglion
left adrenal medulla
left renal & gonadal ganglia
caudal mesenteric ganglion
left hypogastric nerve
DIAPHRAGM

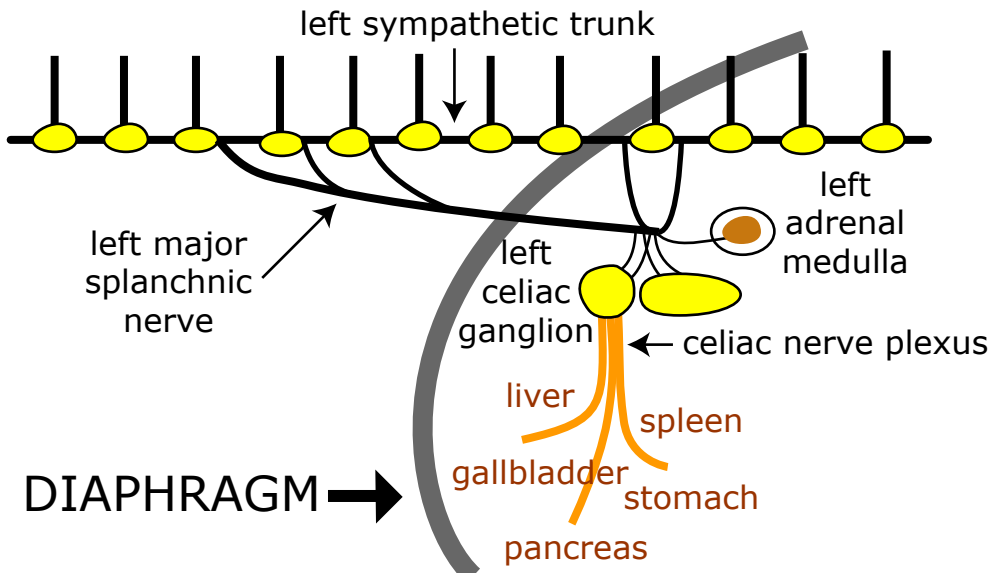
left sympathetic trunk
left major splanchnic nerve
left adrenal medulla
left celiac ganglion
celiac nerve plexus
liver
spleen
gallbladder
stomach
pancreas
DIAPHRAGM

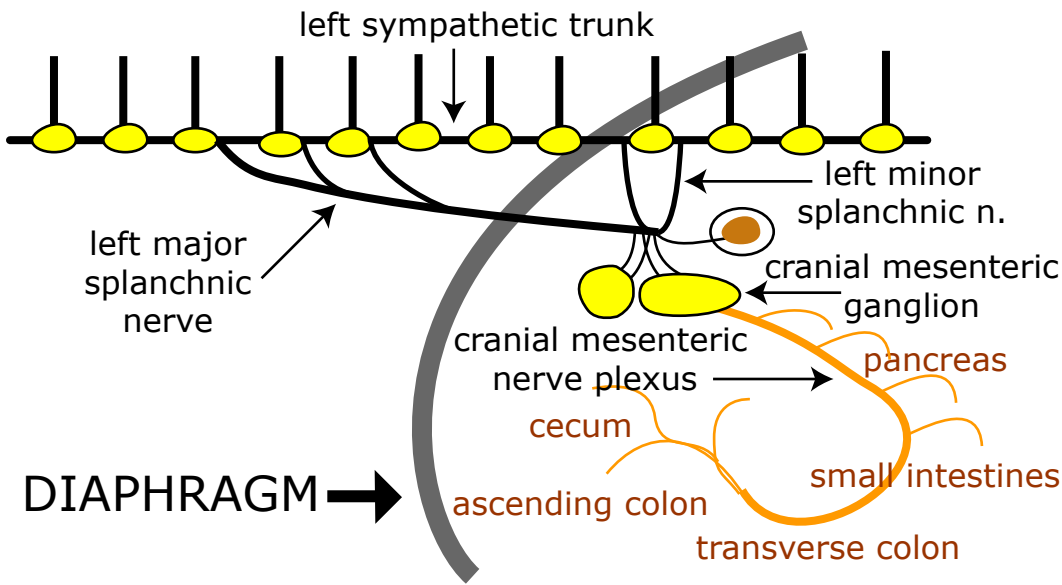
left sympathetic trunk
left minor
splanchnic n.
left major
splanchnic
nerve
cranial mesenteric
ganglion
cranial mesenteric
nerve plexus
pancreas
cecum
small intestines
DIAPHRAGM
ascending colon
transverse colon

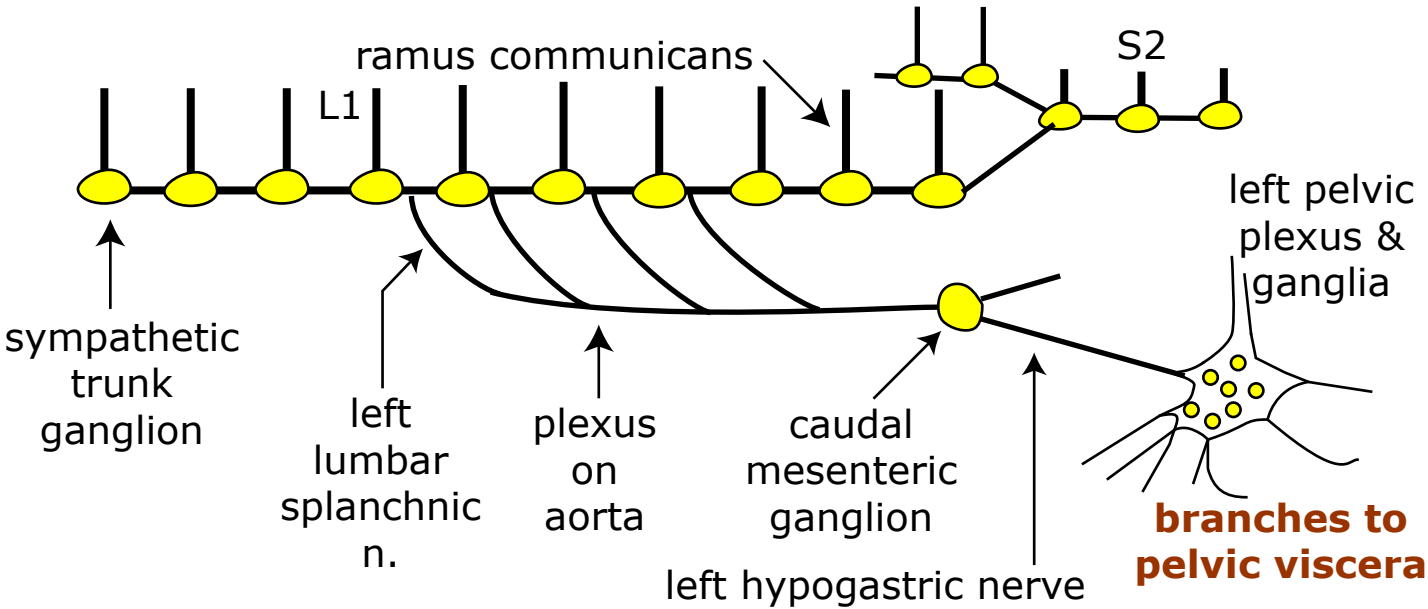
ramus communicans
S2
L1
left pelvic plexus & ganglia
sympathetic trunk ganglion
left lumbar splanchnic n.
plexus on aorta
caudal mesenteric ganglion
left hypogastric nerve
branches to pelvic viscera

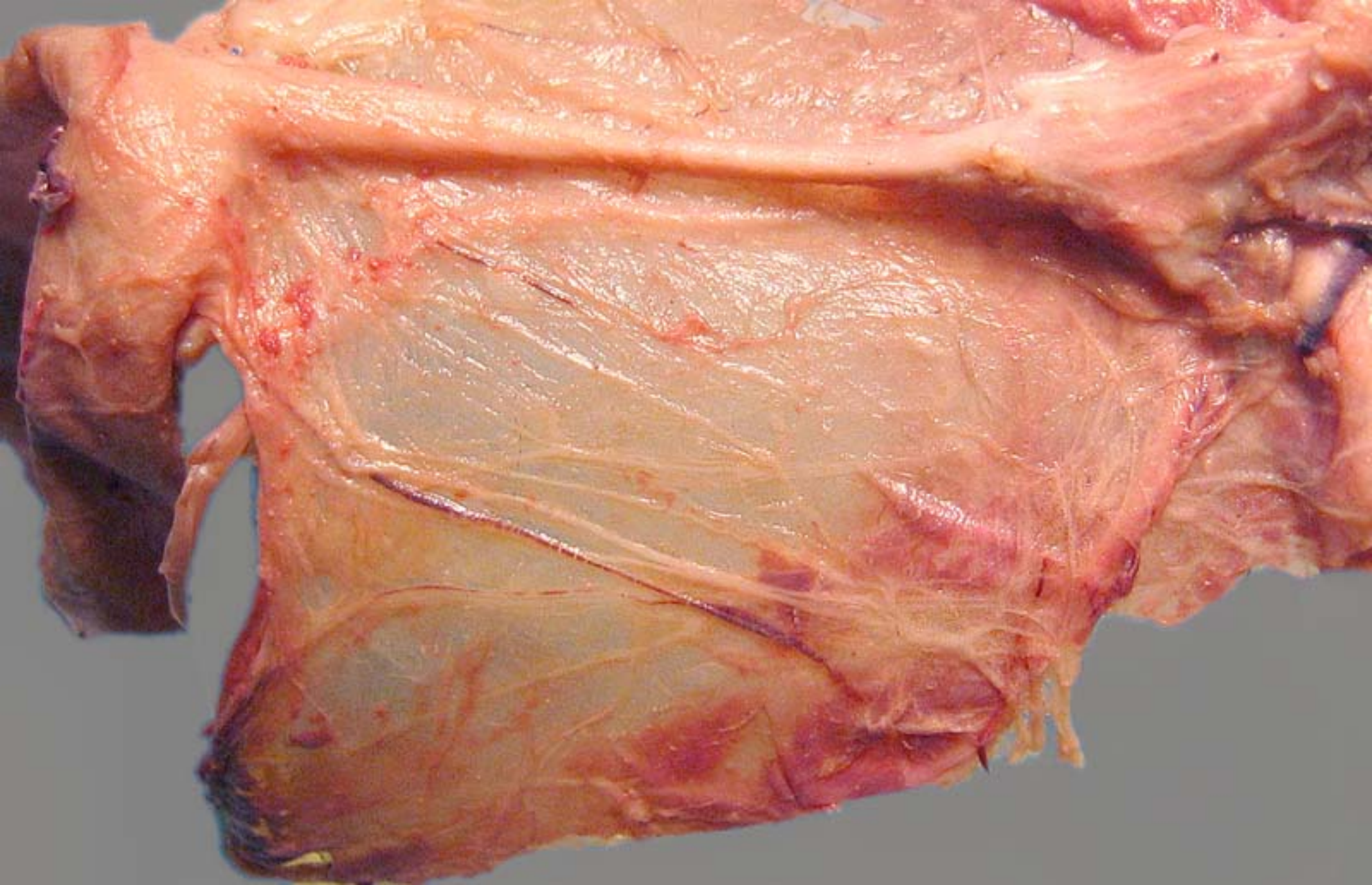

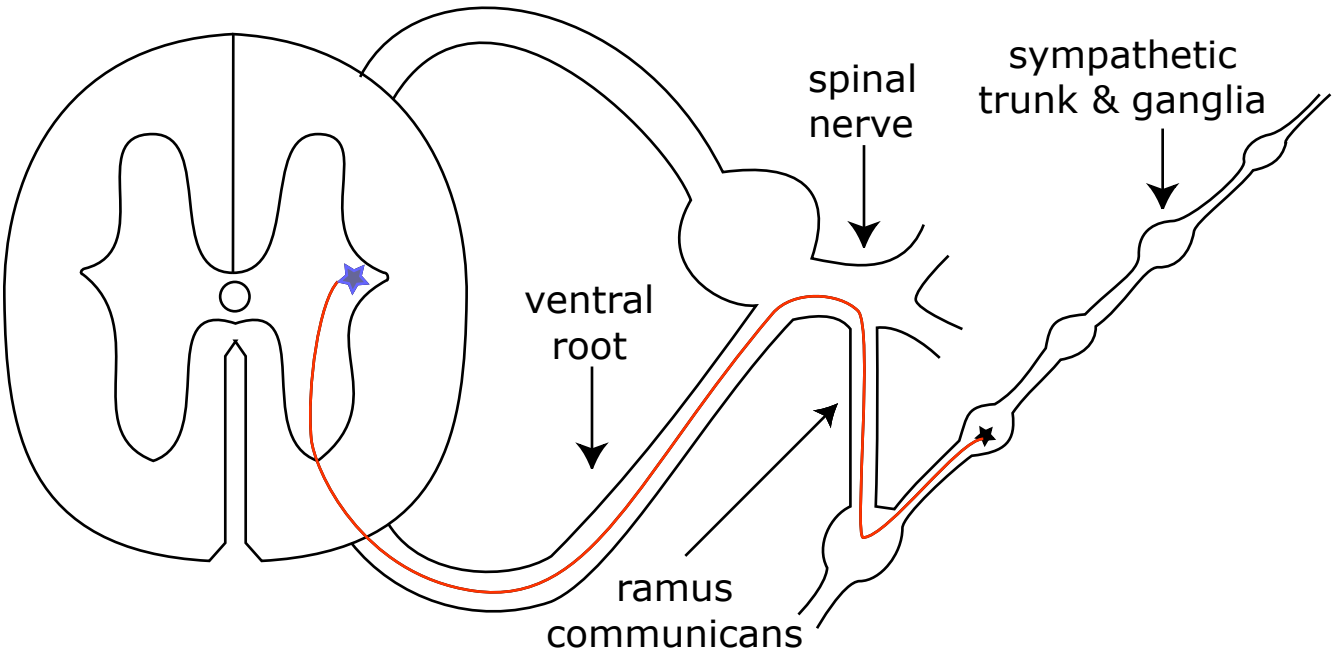
spinal
nerve
sympathetic
trunk & ganglia
ventral
root
ramus
communicans

Autonomic Preganglionic Pathways