Parasitic Diseases

Protozoa:

Are single-celled organisms that range from being microscopic to being just visible with the naked eye, some species being transmitted directly between fish while others have indirect life cycles that involve several aquatic organisms.

Impact of the parasite on the host:

1-Exhaustion food of the host specially large parasite or parasite exit in large number.

2-Mechanical injuries, ex. Resultant migration the parasite inside the host.

3- chemical injuries, such poison which produce by parasite.

4- Obstacle physiological function of the host body, some of tape worm absorb vitamin B12 from human (host) leading to anemia.

Ichthyophthiriosis(White Spot, ICH)

One of the most common and serious diseases of fresh water fish of all type infected the skin , gills and fins.

Signs:

1-White nodules on skin (advancedcases).

2-Opaque to white eyes (advancedcases).

3-Positioned in water currents and/or at sides of ponds.

4- Loss of appetite.

5-Ragged fins, skin raised and broken.

6-Mild skin hemorrhaging; striated skin markings or mottling.

Diagnosis:

1-Clinical signs.

2-Take the direct smear from the skin & examine directly by microscope to showed the parasite.

Treatment :

1-Salt (NaCl) 2–5 g/L salt continuous until disease controlled, may be for up to 20 days.

2-Use Malachite green 20 mg / 100 L for 10 days.
3-Use mixture of formalin 3ml + Methylen blue 1gm/100 L for 3 days.

4-Rise the temp.in the aquarium fish to 30 °C the parasite will be killed within 12 hours.

Trypanosoma spp

These blood-dwelling flagellates , which are common in most fish and probably affect all cyprinids are transmitted by fish leeches. The leech acquires these protozoans during a blood meal on an infected fish. The protozoans undergo morphological changes within the leech vector eventually forming the infective (metacyclic) stage that can invade the blood of a fish when the leech next feeds.

Etiology

Trypanosome carassii is the single polar flagellum protozoan parasite which found between the blood cells.

Signs

1-Anemia

2-Ascetis

3-kidney damage

4-Exophthalmia

Diagnosis

Examination a drop of blood for the presence of haemo flagellates.

Control

There are no chemical treatment a viable to eradicate these blood dwelling protozoan , the only control method, where feasible, is to exclude leech vectors from the culture facility.

Chilodonelliasis

Chilodonella is a ciliated protozoan that causes infected fish to secrete excessive mucus. Infected fish may flashand show similar signs of irritation.

Pathogen

Chilodonella cyprini oval shape parasite covered with cilia ,the cell contain granulated cytoplasm one large nucleus and a small anther one with rows of cilia, direct reproduction by simple division on the skin& gills.

Epizootiology

All kinds of fresh water fish have affected during winter 3-18°C and this protozoan can survive low temperatures, even below 5°C .*Chilodonella cyprini* has been recorded in common carp.

Signs & pathological changes:

1-Dark- blue mucous membrane on the skin & gill.

2-Present the necrotic and ulcerative tissue in the affected gills & skin.

3-The skin may become tattered looking & vulnerable to secondary invasion by bacteria.

4-Skin may have mottled and/or grey Appearance.

5-Lethargy, swimming slowly, head up position, often near surface and edges.

6- Ragged fins.

Diagnosis:

1-Signs & pathological changes.

2-Laboratory examination .

Treatment & control

1-NaCl bath 2.5% for 10 minutes

2-Malachite green 20 mg / 100L for 24 hours. or 1gm / 1m2 for long period repeated 2-3 times.

3-Avoid overcrowding , good water contents O2 &ph., quarantine all new spawners until being sure that they are free from the parasites.

Trichodinasis

Ciliated external protozoa found on the skin, gills the disease affect all kinds of fresh – water fish .

Pathogen

Trichdina alburni is reported in Iraq by (Shemis – Al-Deen,1971 and Khalifa , 1978). The protozoa is circular in shape surrounded by the cilia , with a central ring surrounded by hooks 20-32 as a disc for attachment with a large & a small nucleus.

Signs & lesions

1-Dark – blue mucous membrane.

2-Dead and necrotic skin & gill tissue .

3-Itching the body with the stones inside the ponds.

Diagnosis

Taken the smears from skin and gills for detected the parasite.

Treatment

1-NaCl bath 10-15 gm. / L for 10 minutes.

2-Malachite green 1gm / 400 L for minutes.

3-Potassium permanganate 1gm / 500 L. for 30 minutes.

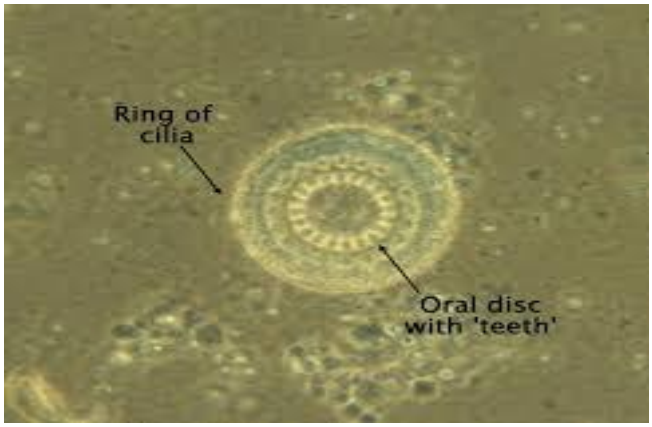

Mxosporidia (Nodular disease)

Mxosporidiaare parasites that are widely dispersed in native and pond-reared fish populations. Most infections in fish create minimal problems, but heavy infestations can become serious, especially in young fish.

Clinical signs

1-Vary, depending on the target organ. For example, fish may have excess mucus production, observed with infections.

2-White or yellowish nodules may appear on target organs.

Control

Give the NaCl treatment at 3-5% .

Nematode (Roundworm)

Infections in Fish Nematodes are smooth, cylindrical, relatively long worms which distinguishes them from the flatter, segmented tape worms and from the stouter and shorter monogenes (flukes).

Epizootiology

Nematodes, or roundworms, infect many different species of fresh and wild fish. High numbers cause illness or even death. fish become infected with nematodes if they are fed live foods containing infective life stages and allow nematodes to complete their life cycle (intermediate hosts). Some nematodes can be transmitted directly from fish to fish.

Signs & lesions

1- Found the adult nematodes are typically in fish intestinal tracts ,adult and other life stages can be found in almost any organ, most commonly present

in muscle, the liver, and tissues surrounding the internal organs.

2-Hemorrhaging.

3-Present the inflammation ,and necrosis (presence of dead and dying tissue) and cystsor granulomas.
4- Granulomas formed around worms can look like little brown “rock-like” areas in the shape of the worm, but they will be surrounded by a distinct clear area at their very edge.

5-Abdominaldistension.

6-Reduced growth.

7-Reduced reproductive capacity.

Diagnosis

1-Infectionsby nematodes in the skin or muscle may be visible or be suspected if lumps or grub-like growths are seen.

2-signs & lesions.

3-Microscopic examination for presence of nematode eggs ,larvae, or adults .

Treatment

Mixed2 grams of levamisole with 1kg of food fed once a week for three weeks, with a repeat treatment in two to three weeks .

Prevention

1-Cleaning and sterilizing ponds is an effective way of reducing the numbers of the intermediate hosts of some nematode species.

2-Preventive medicine can also help the producer avoid illness and production declines.

Cestodes

Cestodes, also called tape worms ,are found in awide variety of animals ,including fish Cestodes infect the alimentary tract, muscle or other internal organs .Larval cestodes called plerocercoids are some of the most damaging parasites to fresh water fish.

Effected the Cestodes

Problems also occur when the cestode damages vital organs such as the brain ,eye or heart. One of the most serious adult cestodes that affect fish is the Asian tape worm.

Treatment

Praziquantelat2–10mg/L for 1to3 hours in abath is effective in treating adult cestode infections in or namental fish.

10-Monogeneans

Monogeneans (skin and gill flukes), are widely distributed in the industry over the last 10 years, and the parasites now occur on most farms. This parasite may cause stress, poor feeding response and growth, tissue damage and interference with gill function, predisposing the fish to fungal and bacterial diseases.

Signs

1- Flashing

2-Excessive mucus production onskin and gills

3-Gill hyperplasia

4-Loss of appetite

5-Emaciation (heavy, prolonged infestations)

Diagnosis

Easily identified; microscopic examination of gill at 40– 100×magnification both adults (gill)and juveniles (skin) show characteristics tretch and recoiling motion.

Treatment

1-Trichlorfon 0.5 mg/L active ingredient, in definite bath.

2-Formalin 30 mg/L (when water <25°C),maintain 24 h aeration for 4–5 days monitor DO daily.

Prevention

Quarantine and treat all incoming fish prophylactically (2–5 g/L plus 30 mg/L formalin), especially fingerlings prior to stocking. Gill flukes are usually indicators of poor water quality, improve water quality. Frequently monitor gill fluke numbers. Monogeneans can be persistent in tank systems necessitating regular treatments and periodic drying. Dry ponds regularly and use calcium oxide(CaO) liberally on any persistently, damp areas.

11-Copepods

Copepods are crustaceans with a complex life cycle, developing through egg, nauplii and copepodid larval stages before attaching and maturing as adults on the host. The fresh water, parasitic copepods, Lernaea spp. And Ergasilus spp. Lernaea spp. (anchor worm)Anchor worms possess anchor -like processes for securing themselves to the host. common 25 carp (*Cyprinus*

carpio) are often carriers of this parasite. Anchor worm is more common in summer ,but the parasite can occur year round .Marketability of fish infested with Lernaeais compromised due to the presence of small, red lesions.

a-*Erqasilus spp.*

Ergasilids are often described as „gill maggots" due to the appearance of white egg sac sattached to the adult females. The parasite"s clasping attachment causes severe gill damage , interference with gill function ,relatively poor growth and were easily stressed during harvest. Parasites were attached to the gills. No mortalities were recorded in ponds. Damage to gill tissue caused by ergasilids can lead to secondary bacterial or fungal infections.

Signs

1- Flashing

2-Loss of appetite

3-Poor growth

4-Hemorrhaging of fins

5-Patchy/blotchy, dark skin

6-Stress following handling

7-Gill hyperplasia

Diagnosis

23 Macroscopic examination of gills, „gill maggots"; easily recognisable on gill tissue at 40× magnification; immature forms may not be grossly visible.

Treatment

• Trichlorfon0.5 mg/L activeing redient; or Salt (NaCl), 10 g/L continuous for3 days.

Prevention

Quarantine and prophylactic treatment prior to stocking; lowering of stocking density; improvement in water quality; use of high quality feeds.

b-Lernaea spp. (anchor worm)

Anchor worms possess anchor -like processes for securing themselves to the host Common carp (*Cyprinus carpio*) are often carriers of the parasite. It can infest individual fish in high numbers (100‟s) without causing mortality; however, poor feeding response and growth has been recorded. Attachment sites are often areas for secondary bacterial or fungal infections. Anchor worm is more common in summer, but the parasite can occur year round. Marketability of fish infested with Lernaea is compromised due to the presence of small, red lesions.

Signs

1-Anchor worms clearly visible to naked eye.

2-Haemorrhaging and red lesions at site of attachment .

3-Emaciation and poor growth.

4-Flashing.

Diagnosis

Macroscopic examination of external features of fish; gravid females easily recognisable by eye attached to gills and skin, often on areas having „softer“ scale cover such as soft ray tissue, mouth and nares; Microscopic and macroscopic examination of gills; small immature stages, such as copepodids may not be grossly visible.

Treatment

Tanks:

- Removal of individual parasites with forceps.
- Trichlorfon 0.25 mg/L activeing redient, indefinite bath.
- Salt 10 g/L, 1 h bath, repeat daily.

Ponds/cages:

- Trichlorfon 0.5 mg/L active ingredient, indefinite bath; repeat every 7 days for 28 days.

- Repeated treatments required to prevent reinfestation by emerging larval stages of Lernaea.

Prevention

Quarantine and prophylactic treatment prior to stocking; lowering of storage reservoir free of carp and other fish.